

Diagnosis and treatment of demodicosis in dogs and cats

Clinical Consensus Guidelines of the World Association for Veterinary Dermatology

Ralf S. Mueller* , Wayne Rosenkrantz†, Emmanuel Bensignor‡ , Joanna Karaś-Tęcza§, Tara Paterson¶ and Michael A. Shipstone**

*Centre for Clinical Veterinary Medicine, LMU Munich, Veterinaerstraße 13, 80539 Munich, Germany

†Animal Dermatology Clinic, 2965 Edinger Ave, Tustin, CA 92780, USA

‡Dermatology Referral Service, 75003 Paris, 35510 Cesson-Sévigné, and 44000 Nantes, France

§Dermawet Dermatology Service for Dogs and Cats, Odyńca 37 lok.1/2, 02-606 Warszawa, Poland

¶Small Animal Medicine & Surgery Department, School of Veterinary Medicine, St. George's University, PO Box #7, St George's, Grenada West Indies

**Dermatology for Animals, 263 Appleby Road, Stafford Heights, Brisbane, Queensland 4053, Australia

Correspondence: Ralf S. Mueller, Centre for Clinical Veterinary Medicine, LMU Munich, Veterinaerstraße 13, 80539 Munich, Germany.

E-mail: R.Mueller@lmu.de

Background – Demodicosis is a common disease in small animal veterinary practice worldwide with a variety of diagnostic and therapeutic options.

Objectives – To provide consensus recommendations on the diagnosis, prevention and treatment of demodicosis in dogs and cats.

Methods and materials – The authors served as a Guideline Panel (GP) and reviewed the literature available before December 2018. The GP prepared a detailed literature review and made recommendations on selected topics. A draft of the document was presented at the North American Veterinary Dermatology Forum in Maui, HI, USA (May 2018) and at the European Veterinary Dermatology Congress in Dubrovnik, Croatia (September 2018) and was made available via the World Wide Web to the member organizations of the World Association for Veterinary Dermatology for a period of three months. Comments were solicited and responses were incorporated into the final document.

Conclusions – In young dogs with generalized demodicosis, genetic and immunological factors seem to play a role in the pathogenesis and affected dogs should not be bred. In old dogs and cats, underlying immunosuppressive conditions contributing to demodicosis should be explored. Deep skin scrapings are the diagnostic gold standard for demodicosis, but trichograms and tape squeeze preparations may also be useful under certain circumstances. Amitraz, macrocyclic lactones and more recently isoxazolines have all demonstrated good efficacy in the treatment of canine demodicosis. Therapeutic selection should be guided by local drug legislation, drug availability and individual case parameters. Evidence for successful treatment of feline demodicosis is strongest for lime sulfur dips and amitraz baths.

Accepted 12 May 2019

Sources of Funding: The WAVD supported the travel of Ralf Mueller to the North American Veterinary Dermatology Forum 2018 in Maui, HI, USA to present the preliminary manuscript for first feedback, otherwise it was self-funded.

Conflicts of Interest: Ralf Mueller has been a consultant, lecturer or has received financial support for studies from Bayer Animal Health (manufacturer of Advocate), Elanco Animal Health (manufacturer of Interceptor and Credelio), Merial (manufacturer of Ivomec and Nexgard), MSD (manufacturer of Bravecto), Novartis (manufacturer of Interceptor) and Zoetis (manufacturer of Mitaban, Simparica and Stronghold/ Revolution).

Wayne Rosenkrantz has been a consultant, lecturer or has received financial support for studies from Merial (manufacturer of Ivomec and Nexgard), Merck Animal Health (manufacturer of Bravecto), Elanco Animal Health (manufacturer of Interceptor and Lotilaner) and Zoetis (manufacturer of Mitaban, Simparica and Stronghold/ Revolution).

Emmanuel Bensignor has been a consultant, lecturer or has received financial support for studies from Merial (manufacturer of Ivomec and Nexgard), Merck Animal Health (manufacturer of Bravecto), Elanco Animal Health (manufacturer of Interceptor and Credelio) and Zoetis (manufacturer of Mitaban, Simparica and Stronghold).

Joanna Karaś-Tęcza has lectured for Bayer Animal Health (manufacturer of Advocate), MSD (manufacturer of Bravecto), Zoetis (manufacturer of Mitaban, Simparica and Stronghold/Revolution).

Tara Paterson has received financial support for studies from Bayer Animal Health (manufacturer of Advocate).

Michael Shipstone has been a consultant, lecturer or has received financial support for studies from Merck Animal Health (manufacturer of Bravecto), Elanco Animal Health (manufacturer of Interceptor and Credelio) and Zoetis (manufacturer of Mitaban, Simparica and Stronghold).

Table of Contents

| | |
|--|-----------|
| Summary of statements | 6 |
| 1 Introduction | 6 |
| 2 Pathogenesis | 7 |
| 2.1 Immunology | 7 |
| 2.2 Genetics of juvenile demodicosis | 8 |
| 3 <i>Demodex</i> species in the dog and cat | 8 |
| 4 Clinical signs in dogs | 8 |
| 5 Clinical signs in cats | 9 |
| 6 Diagnosis | 10 |
| 6.1 Deep skin scrapings | 10 |
| 6.2 Trichograms | 11 |
| 6.3 Tape strips (“Scotch tape™ tests”) | 11 |
| 6.4 Skin biopsy (histopathological investigation) | 11 |
| 6.5 Other methods of mite detection | 11 |
| 6.6 Diagnosing bacterial infections | 12 |
| 6.7 Breeding considerations | 12 |
| 7 Treatment | 12 |
| 7.1 General considerations | 12 |
| 7.2 Amitraz | 13 |
| 7.3 Ivermectin | 14 |
| 7.4 Milbemycin oxime | 15 |
| 7.5 Moxidectin | 15 |
| 7.6 Doramectin | 16 |
| 7.7 Isoxazolines | 17 |
| 7.7.1 Fluralaner | 17 |
| 7.7.2 Afoxolaner | 17 |
| 7.7.3 Sarolaner | 18 |
| 7.7.4 Lotilaner | 19 |
| 7.8 Other drugs | 19 |
| 7.9 Treatment of feline demodicosis | 19 |
| 8 Prognosis and future outlook | 20 |
| References | 21 |

Summary of statements

Diagnosis and treatment of demodicosis in dogs and cats

- 1 In young dogs with generalized demodicosis a temporary immune alteration most likely plays an important role in the pathogenesis. In older dogs, the disease may be associated with an immunosuppressive condition or treatment. However, other hitherto unknown factors also may play a role. In cats, demodicosis is usually associated with other diseases, with the exception of the contagious *Demodex gatoi* that can also affect otherwise healthy cats.
- 2 In young dogs, demodicosis has a genetic basis and most likely multiple genes are involved
- 3 In dogs, two *Demodex* species occur, the shorter *D. canis* and the longer *D. injai*. In cats, the shorter *D. gatoi* has a more regional occurrence and different clinical signs than the classical *D. cati*.
- 4 Demodicosis in dogs is characterized by alopecia and comedones, follicular casts, papules and pustules. In more severely affected dogs crusting with secondary bacterial infections and systemic signs may develop. Dogs with demodicosis due to *D. canis* also can exhibit pruritus, especially when secondary infection is present. *Demodex injai* occurs more often in terrier breeds and additionally causes excessive greasiness. In cats, *D. cati* shows similar clinical signs, whereas by contrast infestations with the contagious *D. gatoi* often lead to truncal pruritus.
- 5 Deep skin scrapings (currently the diagnostic method of choice), trichograms, tape strips and examinations of exudate may be useful in identifying *Demodex* mites. More than one mite on any given test is an indication of clinically relevant demodicosis.
- 6 Dogs with generalized demodicosis and their parents should not be bred.
- 7 Treatment for generalized demodicosis should be monitored clinically and microscopically every month until the second negative skin scraping. Miticidal therapy should be continued four weeks beyond the second set of negative monthly scrapings to decrease the risk of a disease recurrence.
- 8 In dogs with demodicosis, systemic antibiotics will typically not be needed and topical antibacterial therapy combined with good miticidal agents will be sufficient unless severe bacterial infection is present.
- 9 Weekly amitraz rinses at 0.025–0.05% are effective for canine demodicosis; long-haired animals should be clipped.
- 10 Oral ivermectin at 0.3–0.6 mg/kg daily, moxidectin at 0.3–0.5 mg/kg daily, milbemycin oxime at 1.0–2.0 mg/kg daily and doramectin injected subcutaneously every week at 0.6 mg/kg are effective therapies for canine demodicosis, but an initial gradual dose increase is recommended for systemic moxidectin and ivermectin to identify dogs sensitive to toxicosis induced by those macrocyclic lactones. Topical moxidectin/imidacloprid should be considered for mild-moderate cases of canine demodicosis.
- 11 A number of studies have evaluated the efficacy of isoxazolines for canine demodicosis in pet dogs. The published data are very encouraging and make this drug class an excellent treatment option for dogs with demodicosis.
- 12 Demodicosis in cats may be treated with weekly lime sulfur dips at a concentration of 2% or amitraz baths at a concentration of 0.0125%. An easier alternative may be weekly administration of a spot-on containing moxidectin/imidacloprid.

1 Introduction

In previous clinical consensus guidelines, the World Association of Veterinary Dermatology (WAVD) has made an effort to provide up-to-date and relevant information about certain topics available worldwide, written by international panels reflecting expert opinions from several parts of the world and accessible to everybody worldwide.^{1,2} The WAVD invited the authors of this manuscript to contribute to clinical consensus guidelines about demodicosis. Authors initially agreed on responsibilities of each individual for specific sections of the manuscript,

then performed a literature search and gathered published evidence for their individual sections. Where published studies were lacking, textbooks, abstracts presented at veterinary meetings and expert opinions were used. After each section was drafted, the complete manuscript was reviewed by each author. Comments on the whole manuscript were discussed and a preliminary draft of the complete manuscript was posted on the WAVD website and presented at the North American Veterinary Dermatology Forum meeting in Maui, HI, USA, 2018 and the European Veterinary Dermatology Congress in Dubrovnik, Croatia, 2018 where feedback was

requested. This feedback was discussed and a final version of the manuscript was agreed on by all authors before submission to the journal.

2 Pathogenesis

Demodicosis is a common disease in canine practice^{3,4} caused by a proliferation of *Demodex* mites. These mites are normal commensal organisms in the hair follicles of many mammals.^{5–10} In the dog they are transmitted during the first days of life from the dam to the puppies.¹¹ In most species, demodicosis occurs only when animals are immunocompromised due to other diseases or undergoing immunosuppressive therapies. Demodicosis in immunosuppressed individuals has been reported in humans, dogs and cats amongst others.^{12–18} With the exception of *Demodex gato* in the cat, the dog is the only species where young and otherwise healthy animals develop demodicosis. This juvenile demodicosis has been presumed to be due to cell-mediated deficiency.¹⁹

2.1 Immunology

Early studies showed a normal humoral response, but decreased lymphocyte blastogenesis in young dogs with naturally occurring demodicosis.^{20,21} Treatment of puppies with anti-lymphocyte serum led to generalized demodicosis in eight puppies whereas their untreated littermates remained healthy.²² Subsequently, a T-cell exhaustion characterized by low numbers of circulating CD4⁺ T cells,²³ together with increased serum concentrations of interleukin (IL)-2,²⁴ IL-5, IL-6²⁵ and²⁶ IL-18,²⁴ and the immunosuppressive cytokines IL-10^{27,28} and TGF-beta²⁵ were reported in a number of studies comparing dogs with generalized demodicosis to healthy controls.^{9,27–29} By contrast, the proinflammatory cytokine TNF-alpha was reduced in dogs with demodicosis.²⁸ The CD4:CD8 ratio was lower and the number of CD8-positive cells was reported to be increased in dogs with generalized demodicosis.²⁹ However, it is unclear, whether those changes are a consequence of the demodicosis or contribute to the pathogenesis. Histologically, demodicosis is characterized by a mural folliculitis with infiltrating CD8⁺ cytotoxic T cells, which resolves quickly with resolution of the demodicosis.³⁰ MHC class II receptors are upregulated in the skin of dogs with demodicosis, particularly in keratinocytes.³¹

The presumption that immunosuppression is the cause of the demodicosis is further supported by a severe combined immunodeficiency (SCID) mouse model. SCID mice, which have no B and T cells, received skin grafts from dogs which were later infected with *D. canis* collected from a dog with demodicosis. Within one to three months, mites proliferated in the grafted canine skin and not the surrounding murine skin.³² In another immunodeficient double knock-out mouse model lacking CD28 (a co-stimulatory molecule involved in T-cell activation) and STAT6 (essential for a pathway that plays a role in IL-4 signal transduction and Th2 differentiation), mice developed a severe dermatitis due to a proliferation of *Demodex* mites.³³ However, in this model, demodicosis was accompanied by a prominent dermal infiltration of CD4⁺ and CD8⁺ T cells, increased concentrations of IL-12, IFN-

gamma and IgG2 indicating a prominent Th1 response, that was markedly reduced once the *Demodex* mites were treated with amitraz.³³ The alleviation of the Th1 response with miticidal treatment in the double knock-out mouse model does not seem to be in concordance with a defect of cell-mediated immunity as a cause of demodicosis. In another study, canine skin grafts on Rag2 knock-out mice were infected with *D. canis* mites.³⁴ Mites proliferated in the grafts, but clinical lesions did not develop. Nine weeks after infection, some grafts were injected with canine peripheral blood mononuclear cells (either nonstimulated or stimulated with phytohaemagglutinin and IL-2). One month later, mite numbers were highest in the grafts injected with stimulated PBMCs (those mice also developed canine serum IgG antibodies), lower in grafts not injected at all with PBMCs and lowest in the grafts injected with nonstimulated PBMCs.³⁴

The pathogenesis of demodicosis may be more complicated or it may be different in the juvenile dog or in different dog breeds. Possibly, a functional Th2 response is more relevant for mite control than thought previously. One study evaluated only pit bull terrier-type dogs with generalized demodicosis with age- and breed-matched controls, and reported significantly higher serum IgA, IL-2, IL-18 and monocyte chemoattractant protein-1 concentrations in affected dogs, also pointing to an at least partially increased immune response in this breed.²⁴ A further study reported increased Toll-like receptor (TLR)-2 and decreased TLR-4 and TLR-6 in dogs with demodicosis compared to normal controls.³⁵ The downregulation of TLRs in affected dogs may be induced by the mites as a strategy to decrease the host immune response. Alternatively, it could be a predisposing factor for disease development or an incidental finding not influencing the disease. Further studies are required to define the role of TLRs in the development of canine demodicosis.

Initially, there was debate as to whether the secondary bacterial infection seen with generalized demodicosis was contributing to, or in some way causing, those immunological changes.^{36,37} However, based on the published data this seems less likely^{38,39} and at least the decreased lymphoblastogenesis seems to be a consequence rather than a cause of the disease.^{39,40} Not surprisingly, demodicosis is accompanied by an increase in markers for oxidative stress.⁴¹

As the overwhelming majority of affected juvenile dogs do not suffer from a recurrence following successful therapy,⁴² it seems likely that the presumed immune aberration is a temporary problem.

The first clinical signs of juvenile demodicosis in dogs typically occur in the first 18 months of life.¹⁹ Adult-onset demodicosis also exists and is comparable to the demodicosis seen in other species. In the dog, this was reported to be associated with diseases or drugs leading to a compromised immune system such as leishmaniasis,⁴³ hyperadrenocorticism,^{14,44} hypothyroidism,¹⁴ neoplasia,¹⁴ babesiosis,⁴⁵ ehrlichiosis,⁴⁵ and glucocorticoid treatment or chemotherapy.¹⁴ Although one report mentioned atopic dermatitis as a frequent concurrent disease, many dogs had received glucocorticoid therapy.⁴⁶ In a retrospective study evaluating a large number of dogs with adult-onset demodicosis in two countries and comparing

those dogs to a control population, hyperadrenocorticism, hypothyroidism and leishmaniosis, but not neoplasia, predisposed dogs to demodicosis.⁴⁷ However, the differentiation of juvenile- and adult-onset demodicosis may be difficult in individual cases. It is more important to identify and correct predisposing factors (such as endoparasitism or underlying diseases) independent of age to achieve the best possible outcome.

In cats, demodicosis has been reported in association with feline immunodeficiency virus,^{18,48,49} xanthoma⁵⁰ and diabetes mellitus.⁵¹ The localized form has been described in lesions of feline squamous cell carcinoma *in situ*.^{52,53}

Consensus Statement 1 In young dogs with generalized demodicosis a temporary immune alteration most likely plays an important role in the pathogenesis. In older dogs, the disease may be associated with an immunosuppressive condition or treatment. However, other hitherto unknown factors also may play a role. In cats, demodicosis usually is associated with other diseases, with exception of the contagious *Demodex gatoi* that also can affect otherwise healthy cats.

In humans, demodicosis is described as a primary immunosuppressive disorder based on a hereditary T-cell defect⁵⁴ or as a consequence of immunosuppression.¹⁷

2.2 Genetics of juvenile demodicosis

For decades, strong breed predilections were reported for canine juvenile demodicosis. In early reports, those lists were largely anecdotal. One large, well-powered study identified a greater than four-fold increased risk of developing generalized demodicosis for the American Staffordshire terrier, Staffordshire bull terrier, Chinese shar-pei and French bulldog.⁵⁵ A further study in the United States identified the English bulldog, pit bull and Sealyham terrier as predisposed breeds for juvenile onset demodicosis.⁴⁶

Those breed predilections and the frequent occurrence of juvenile demodicosis in certain lines, sibling puppies and related dogs make a hereditary basis very likely. In addition, there is anecdotal evidence that preventing affected dogs from breeding decreases the frequency of the disease.¹⁹ However, to the best of the authors' knowledge, only one study has been published evaluating the genetic basis in more detail. In that study, using microsatellite markers, a significant association was found between generalized demodicosis and the DLA haplotypes FH2002, FH2975 and FH2054 in Argentinian mastiffs and boxer dogs.⁵⁶

Demodicosis in juvenile dogs shows a wide variety of clinical signs, from mild, localized alopecia to severe generalized forms with prominent systemic signs. These variations may be seen within the same litter of puppies. In addition, dogs respond differently to the various therapeutic approaches. Thus, it is likely that several genes are involved in the pathogenesis and, thus, more and larger studies are needed to elucidate the genetic background of the disease. Further support for a multi-gene

involvement is the above-mentioned immunodeficient double knock-out mouse strain lacking CD28 and STAT6.³³ By contrast to the double knock-out mice, single knock-out siblings kept in close contact and lacking either CD28 or STAT6 did not show any clinical signs.³³

Consensus Statement 2 In young dogs, demodicosis has a genetic basis and most likely multiple genes are involved.

3 *Demodex* species in the dog and cat

Several mite species have been reported in dogs and cats. In the dog, initially three different species were reported. *Demodex canis* is the most common demodectic mite of dogs. A longer-bodied mite also was reported^{57–60} and named *D. injai* ("inja" being the Zulu name for "dog").⁵⁷ The female adult mites were approximately 50% longer and males 100% longer than adult *D. canis* mites respectively. A short-bodied mite was named *D. cornei* by some authors because it was supposedly found more superficially.^{61–65} Genetic comparisons^{66,67} revealed only one⁶⁶ or two⁶⁷ different species of *Demodex* in the dog: *D. canis* and *D. injai*. In the genetic studies, the short-bodied mite was considered to be a morphological variant of *D. canis*.⁶⁷ In one report it was suggested that *D. cornei* are dead or near-dead *D. canis* mites, further supporting that only two species of mites exist.⁶⁸ However, a taxonomic analysis found the short-bodied mite to be a distinct canine species.⁶⁵

There are three different species of *Demodex* mites in the cat: *D. cati*,⁶⁹ *D. gatoi*⁷⁰ and a third unnamed species.^{13,71} The unnamed species had a longer gnathosoma and a shorter opisthosoma than *D. cati*; the length:width ratio of the opisthosoma was approximately 2:1, whereas in *D. cati* it was approximately 5:1.¹³ By contrast to *D. cati*, *D. gatoi* is contagious and usually causes intense pruritus.^{72,73} It was considered a very regional disease, predominantly diagnosed in the Southeastern United States.⁷³ However, more recently there have been reports of *D. gatoi* infestations in cats from other areas of the world.^{72,74,75}

Consensus Statement 3 In dogs, two *Demodex* species occur, the shorter *D. canis* and the longer *D. injai*. In cats, the shorter *D. gatoi* has a more regional occurrence and different clinical signs than the classical *D. cati*.

4 Clinical signs in dogs

In the dog, localized and generalized forms of demodicosis were differentiated on the basis that the vast majority of dogs with localized demodicosis went into spontaneous remission without treatment.¹⁹ However, the definition of localized demodicosis is subjective and thus different presentations are judged differently by different

breeders and veterinarians. The reported lesion extent consistent with localized disease ranges from four lesions to 50% of the body surface.^{76,77} It is unknown whether the size of a lesion considered localized is influenced by the size of the dog or whether an area with inflammatory lesions such as papules, pustules, exudation, crusting and ulcers is comparable to an area characterized only by alopecia and comedones. This may make the differentiation of localized from generalized disease difficult in some individual cases.

Clinical signs develop after mite proliferation has occurred; they depend on the degree of mite proliferation. Initially, there may be a noninflammatory hypotrichosis/alopecia and/or an inflammatory dermatitis with mild erythema, comedone formation, scaling and associated hypotrichosis/alopecia (Figures 1 and 2). The lesions may be focal or multifocal to coalescing involving large areas of the body. Follicular plugging, dilation and hyperpigmentation of hair follicular ostia may be present and when seen are a clinical clue for the disease. Pedal demodicosis commonly causes quite marked hyperpigmentation (of both follicles and surrounding skin) and may present with significant interdigital inflammation, oedema and pain (Figure 3). In more inflammatory presentations, follicular-oriented papules may develop. Pruritus is generally not thought to be characteristic of milder presentations; however, it is more common if the short-bodied morphological variant of *D. canis*^{61,62} is present and/or if secondary bacterial infection develops. Follicular casts (scale adherent to the hair shafts) may be present.

With more severe or advanced disease (Figures 4 and 5), secondary bacterial infection may lead to follicular pustules, furunculosis with scale, crust, exudation and ulceration with draining tracts. Severe, generalized pustular demodicosis may be painful and associated with hyperpigmentation, lymphadenopathy, lethargy and fever. In those severely affected dogs, septicæmia secondary to bacterial infection is possible and may even have a fatal outcome.

Demodex injai has been reported in several dog breeds but seems over-represented in terrier breeds and their crosses.⁶⁰ Whilst it may be associated with erythema, comedone formation, hyperpigmentation and alopecia,

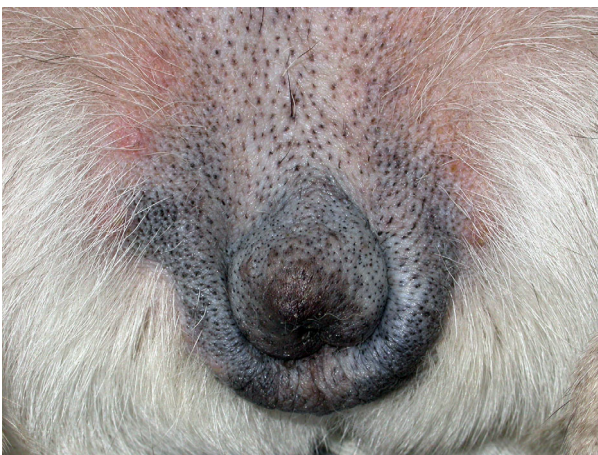

Figure 1. Comedones in the perivulval area of a dog with demodicosis.

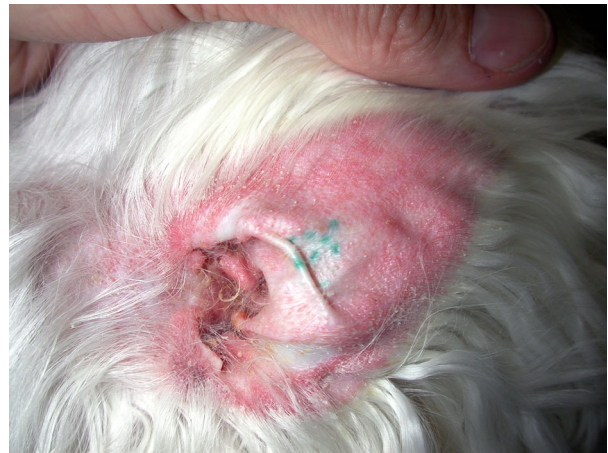

Figure 2. Erythematous and scaly pinna of a dog with demodicosis.

similar to *D. canis*, the most striking and consistent clinical feature is marked greasiness of the dorsal trunk.

Environmental factors such as a high humidity and ambient temperature are anecdotally discussed as leading to more severe clinical signs in the dog, although no scientific studies have been conducted to confirm this statement.

5 Clinical signs in cats

Demodex cati can cause localized or generalized disease and lesions include erythema, hypotrichosis/alopecia,

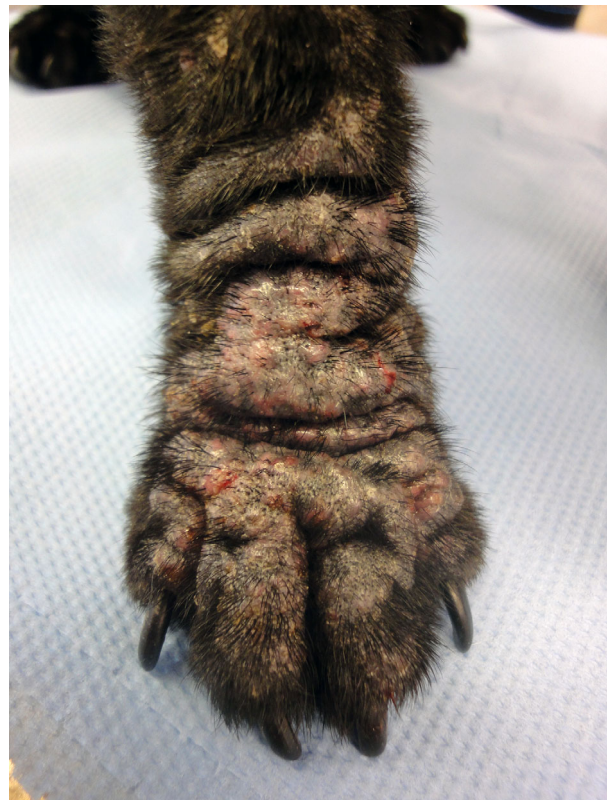

Figure 3. Pododemodicosis in a 1-year-old, male neutered pug with generalized demodicosis.

scale and crusting (Figure 6). Pruritus is variable but may be intense in some individuals. Generalized disease commonly is associated with an underlying disease such as feline immunodeficiency virus,^{18,48,49} xanthoma⁵⁰ or diabetes mellitus.⁵¹ In some cats, no other disease may be identified. *Demodex* mites also have been reported to proliferate within the scaly alopecic lesions of Bowenoid *in situ* carcinoma (BISC).^{52,53}

Demodex gato is a contagious mite that inhabits the stratum corneum (like *Sarcoptes*) and the most common clinical feature is pruritus ranging from mild to very intense. Skin lesions aside from self-induced alopecia and scale (Figure 7) are secondary hyperpigmentation, superficial erosion and ulceration. The changes predominantly are truncal with the ventral abdomen having been reported as a site of predilection.^{72,73}

Consensus Statement 4 Demodicosis in dogs is characterized by alopecia and comedones, follicular casts, papules and pustules. In more severely affected dogs crusting with secondary bacterial infections and systemic signs may develop. Dogs with demodicosis due to *D. canis* also can exhibit pruritus, especially when secondary infection is present. *Demodex injae* occurs more often in terrier breeds and additionally causes excessive greasiness. In cats, *D. cati* shows similar clinical signs, whereas by contrast infestations with the contagious *D. gato* often lead to truncal pruritus.

6 Diagnosis

6.1 Deep skin scrapings

Deep skin scrapings are considered to be the diagnostic tool of choice in most patients with suspected demodicosis.⁷⁸ Samples may be collected with curettes, spatulae, sharp or dull scalpel blades. Placing a drop of mineral oil

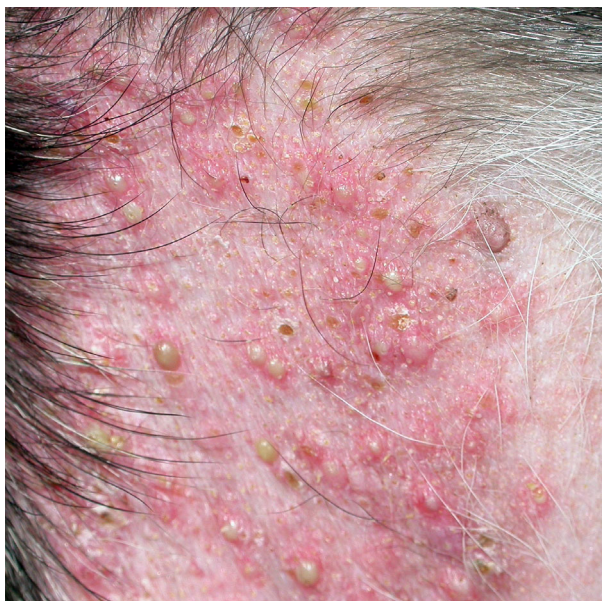

Figure 4. Pustular demodicosis on the ventrum of a dog with generalized demodicosis.

on the sampling instrument or directly on the skin is helpful for better adherence of the sampled debris to the instrument. Multiple scrapings of approximately 1 cm² of affected skin should be performed in the direction of the hair growth and importantly the skin should be squeezed constantly or intermittently during scraping to extrude the mites from the depth of the follicles to the surface. Squeezing the skin has been shown to increase the number of mites found.⁷⁹ Primary lesions such as follicular papules and pustules should be selected in order to obtain the best yield. If at early onset papules and pustules are not present, erythematous, alopecic areas should be chosen. Ulcerated areas are not suitable as it is less likely to find parasites in such areas. The skin is scraped until capillary bleeding occurs indicating sufficient depth of the scraping. The gathered debris should be of reddish to brownish colour, indicating sufficient material (Figure 8). If necessary in a long- or medium-haired dog, lightly clipping the area to be scraped (in the direction of hair growth) will minimize the loss of the scraped material into the surrounding hair. Debris then is transferred to a slide, mixed with mineral or paraffin oil and examined with a cover slip under the microscope at low magnification (overall $\times 40$ or $\times 100$). Recognition of mites is easier with a lowered microscope condenser and decreased light to increase the contrast in the microscope field (Figure 9). Specimens should be evaluated immediately, as anecdotally mite deterioration may occur making accurate identification of numbers and stages more difficult with time.

As *Demodex* mites are part of the normal microfauna, one mite identified on several deep skin scrapings could be a normal but uncommon finding. However, more than one mite is strongly suggestive of clinical demodicosis. If only one mite is found in a dog with compatible clinical signs, further skin scrapings should be performed to confirm the diagnosis. Different life stages (eggs, larvae, nymphs and adults) and their numbers should be recorded and compared from the same sites at each visit to objectively measure the treatment success.

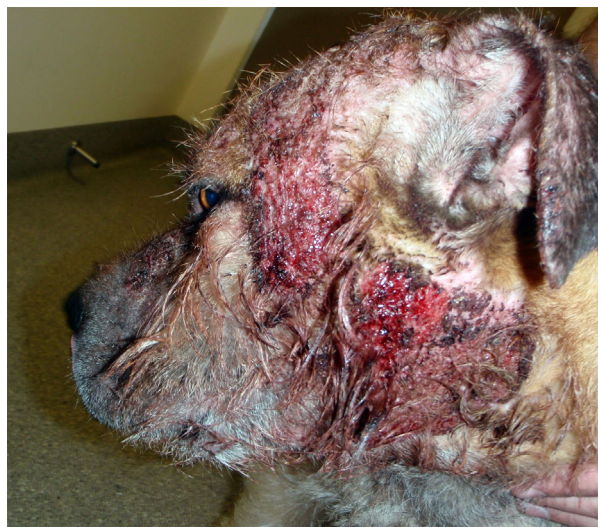

Figure 5. Severe facial demodicosis in a dog.

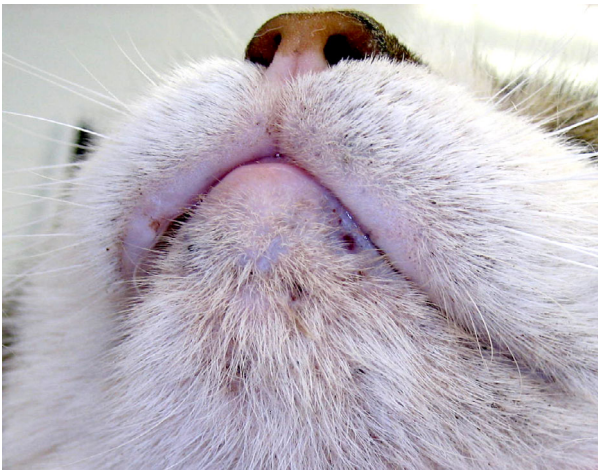

Figure 6. Demodicosis caused by *Demodex cati* in an 8-year-old female spayed domestic short-haired cat with lymphoma.

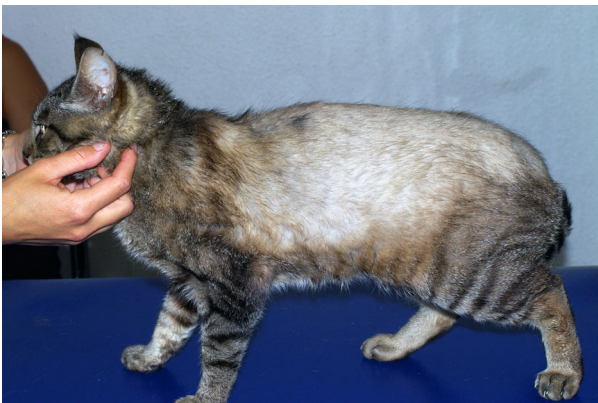

Figure 7. Alopecia due to *Demodex gatoi* in a DSH.




Figure 8. Debris gathered with a deep skin scraping.

6.2 Trichograms

Trichograms have been reported as an alternative to deep skin scrapings^{79,80} and are particularly useful in areas that are difficult to scrape, such as periocular and interdigital areas. An area of 1 cm² should be plucked with forceps in the direction of the hair growth and placed in a drop of mineral or paraffin oil on a slide. The use of a coverslip greatly facilitates thorough and rapid inspection of the specimen (Figure 10). To increase the chance of a

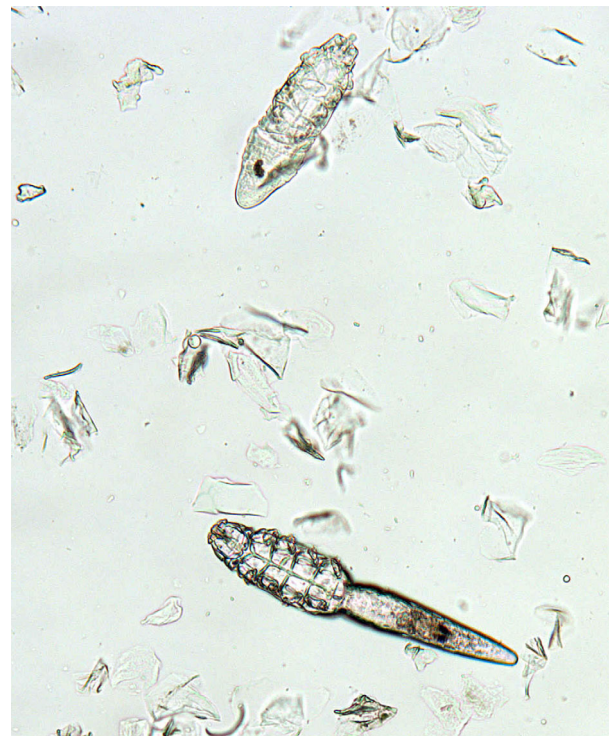

Figure 9. *Demodex canis* mites in a skin scraping ($\times 100$).

positive trichogram, a large number of hairs (50–100) should be plucked, if possible. When performed properly, trichograms have a high diagnostic yield.^{79,80} However, negative trichograms should be followed by deep skin scrapings before ruling out demodicosis. Positive trichograms in healthy dogs are rare.⁸¹

6.3 Tape strips (“Scotch tape™ tests”)

Tape strips also have been reported as an excellent diagnostic method for canine demodicosis.⁸² While squeezing the skin, the acetate tape is pressed onto the skin with the sticky surface down. Although this technique initially was reported to be more sensitive than deep skin scrapings,⁸² follow-up studies have shown contradicting results.^{83,84}

6.4 Skin biopsy (histopathological investigation)

In some rare cases, skin scrapings, trichograms and tape preparations may be negative and skin biopsies for histopathological investigation may be needed to detect the *Demodex* mites in the hair follicles or in foreign body granulomas observed as a consequence of furunculosis. This may be more likely in certain body locations such as the paws and certain breeds such as the shar-pei.

6.5 Other methods of mite detection

Direct examination of the exudate from pustules or draining tracts may reveal mites in some cases. Specimens can be collected by squeezing the exudate onto a glass slide, and visualized by adding mineral oil and a coverslip. In one study, exudate was collected from dogs showing exudative lesions with the blunt side of a second scalpel blade after gently removing the crusts and squeezing the lesion.⁸⁵ In this particular study, the exudate sampling

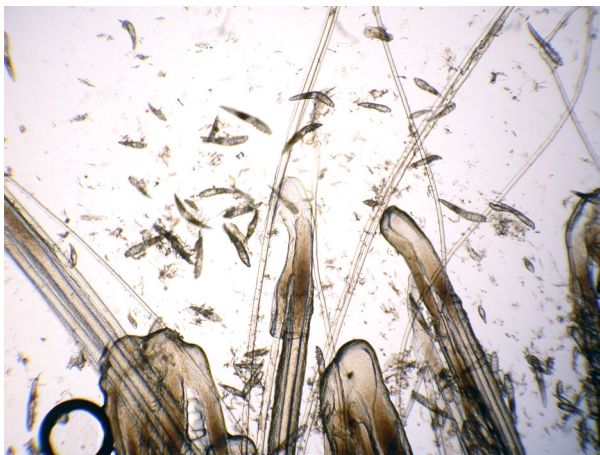


Figure 10. *Demodex canis* mites in a trichogram.

was compared to deep skin scrapings and trichograms and was positive in all dogs sampled. However, this technique is only possible in dogs with more severe forms of demodicosis.

Cytological specimens stained with commercial Romanovsky stains, such as Diff Quik, also may reveal *Demodex* mites (more easily recognized with the condenser lowered for searching). Although this is not a very sensitive method for the diagnosis, it is not uncommon to find mites on the evaluation of cytological samples of dogs with exudative forms of demodicosis.

Faecal flotation was evaluated for diagnosis of canine and feline demodicosis and was reported to yield less mites than skin scrapings and be frequently false-negative.^{74,75,86}

Consensus Statement 5 Deep skin scrapings (currently the diagnostic method of choice), trichograms, tape strips and examinations of exudate may be useful in identifying *Demodex* mites. More than one mite on any given test is an indication of clinically relevant demodicosis

6.6 Diagnosing bacterial infections

Frequently, generalized demodicosis is associated with secondary bacterial infections. Particularly in severe cases involving furunculosis, a bacterial septicaemia is possible. When clinical signs of possible bacterial infection such as pustules or draining tracts are present, an impression smear should be obtained, stained and evaluated for an increased number and/or intracellular location of bacterial organisms. Most commonly, *Staphylococcus pseudintermedius* will be present,⁴² but in some patients, particularly those with furunculosis, Gram-negative rods such as *Escherichia coli* or *Pseudomonas aeruginosa* may dominate. For these cases, a culture and susceptibility testing is indicated.

6.7 Breeding considerations

Canine generalized demodicosis is a relatively frequent and often very severe parasitic skin disease. As many as

0.58% of the dogs in the USA suffer from the generalized form of the disease.⁵⁵ Multiple risk factors are involved in the development of canine demodicosis and one of the most important recognized risk factors is breed predisposition.⁵⁵ Juvenile demodicosis is more common in pure-bred dogs of particular breeds. Selective breeding in order to obtain a certain set of desired characteristics in a particular breed can lead to a reduction of genetic variation within a breed. This may facilitate the clinical expression of recessive genes and in turn can result in a greater susceptibility to certain diseases.

Knowledge about breed predispositions for certain diseases such as demodicosis is useful not only while creating a list of differential diagnoses and when advising clients which breed to purchase, but also when advising breeders. Implementing appropriate prophylactic strategies can markedly reduce the prevalence of generalized juvenile demodicosis in the dog.¹⁹ Excluding bitches from breeding that have given birth to puppies with demodicosis will lead to a prominent decrease of puppies affected with demodicosis.¹⁹ As early as 1981, the American Academy of Veterinary Dermatology adopted a resolution recommending “neutering all dogs who have had generalized demodicosis so that the incidence of the disease is decreased and not perpetuated”.⁸⁷ We recommend that affected dogs or their parents should not be used for breeding. One report recommended that the need to use acaricidal therapy was a determining factor for the exclusion of dogs from breeding, given the advent of isoxazolines used for ectoparasite control, this recommendation is difficult to maintain. It is the consensus of the authors to recommend that dogs with generalized demodicosis and their parents not be bred until further studies are evaluated regarding the impact of isoxazolines.

Consensus Statement 6 Dogs with generalized demodicosis and their parents should not be bred.

7 Treatment

7.1 General considerations

Demodicosis varies from mild localized to severe generalized disease. Mild localized disease will resolve spontaneously in most cases. How many dogs with more severe disease would also resolve spontaneously without treatment is unclear. Although a study has attempted to evaluate the proportion of dogs with the generalized form of the disease that undergo spontaneous remission,⁸⁸ such studies are difficult to conduct and robust data are lacking to answer this question. In addition, in most countries it is considered unethical to withhold treatment of dogs with severe demodicosis and owners of such dogs usually will not consent to observation instead of interventional (and typically efficacious) acaricidal therapy. Nevertheless, there is some evidence that spontaneous remission can occur in a subset of dogs with generalized disease.^{88,89}

Anecdotally, intact female dogs with generalized demodicosis in remission after successful treatment may show disease recurrence when in oestrus. Some of the present authors also have seen this. In a female

Dobermann pinscher four recurrences each associated with oestrus were seen until the owner agreed to neutering. In a study of American Staffordshire terriers, Staffordshire bull terriers and pugs with demodicosis from Sweden, the rate of recurrence was not increased in the group of intact bitches.⁹⁰

In juvenile dogs, treatment of the demodicosis and possibly the secondary bacterial infection, if present, is typically sufficient without the need for further diagnostic investigation. By contrast, for those cats and dogs with adult-onset disease, the possibility of an underlying, immunosuppressive disease should be investigated. In one dog with adult-onset demodicosis, treatment of the primary disease resulted in resolution of the demodicosis.⁵⁷ In another study evaluating dogs with adult-onset demodicosis,¹⁴ four of nine dogs in which the primary disease was diagnosed and treated successfully were cured. By contrast, only three of 25 dogs in which no underlying disease was diagnosed or the concurrent disease could not be treated were cured. However, even extensive investigation for underlying diseases is not always successful in identifying a cause for the demodicosis. In one larger study, 30% of the adult dogs had idiopathic demodicosis.¹⁴

Regardless of the specific miticidal therapy, treatment success is monitored both clinically and by repeated skin scrapings. Generally, it is recommended to examine dogs and cats with demodicosis monthly. At each recheck, skin scrapings are taken from the same sites as in previous visits. In addition to clinical improvement, the numbers of mites and immature stages should decrease with each visit. If clinical improvement does not occur and mite numbers fail to improve, a change in therapy should be considered.⁴² Clients need to be informed that their pets may look better before the mites have been eliminated, thus the need to comply with monthly evaluations until the patient is deemed parasitologically cured. They also need to be educated about the potentially slow improvement in clinical signs over several weeks to months.

Miticidal therapy should be continued four weeks beyond the second set of negative monthly scrapings to decrease the risk of a disease recurrence.⁴² In dogs that responded very slowly to therapy, treatment may be extended even further. In a systematic review of 124 dogs reported to have failed the initial therapy, two thirds responded to a change of therapy.⁴² Similarly, of 40 dogs with recurring demodicosis within 12 months after initially responding to therapy, more than two thirds went into remission after another treatment course with the same or an alternative medication.⁴² A follow-up of at least 12 months after treatment cessation has been recommended before calling a dog cured, although in some studies the disease recurred after more than 12 months of remission in a few dogs.⁴²

Consensus Statement 7 Treatment for generalized demodicosis should be monitored clinically and microscopically every month until the second negative skin scraping. Miticidal therapy should be continued four weeks beyond the second set of negative monthly scrapings to decrease the risk of a disease recurrence.

In most dogs with demodicosis, secondary bacterial infection will develop with time. In the past, systemic antibiotic therapy was recommended for all dogs in which a secondary bacterial infection could be demonstrated clinically and cytologically. However, in a randomized controlled trial evaluating 58 dogs with generalized demodicosis, half of the dogs were treated with systemic antibiotics in addition to miticidal therapy with daily ivermectin and topical weekly benzoyl peroxide shampoo, the other half received only shampoo and ivermectin.⁹¹ There was no significant difference between groups in the time to cytological resolution of the bacterial pyoderma, the time to negative skin scrapings and to clinical remission. Systemic antibiotics may not be needed because topical therapy with antimicrobial shampoo was as effective in cases with mild to moderate secondary pyoderma.⁹¹ In dogs with severe deep pyoderma, previous antibiotic treatment or dogs with bacterial infections associated with the presence of rod-shaped bacteria on cytological samples then bacterial culture and sensitivity should be recommended as a basis for the selection of appropriate antibiotic therapy. As the prevalence of skin infections with multiresistant bacteria is increasing, antibiotic stewardship with a judicious use of systemic antibiotics is recommended,² and topical antibacterial therapy alone should be considered for the majority of dogs with demodicosis.

Consensus Statement 8 In dogs with demodicosis, systemic antibiotics will typically not be needed and topical antibacterial therapy combined with good miticidal agents will be sufficient unless severe bacterial infection is present.

7.2 Amitraz

Amitraz as a leave-on rinse has been the approved mainstay treatment for canine generalized demodicosis in many countries for decades. It is a diamide, N'-(2,4-dimethylphenyl)-N-[(2,4-dimethylphenyl) imino]1-8 methyl-N-methylmethanidamide.⁹² Amitraz is a monoamine oxidase inhibitor, an alpha 2-adrenergic agonist and inhibits prostaglandin synthesis.⁹² In addition to the rinse, amitraz also is available in a 9% tick preventive collar, reported as a sole therapy⁹³ and in combination with other ectoparasiticides.⁹⁴ However, amitraz tick collar efficacy for canine demodicosis is controversial. Pilot studies of the spot-on products (in combination with metaflumizone⁹⁵⁻⁹⁷ and with fipronil⁹⁸) reported successful treatment of canine generalized demodicosis. However, pemphigus foliaceus-like drug reactions were reported with both products.^{16,99} The manufacturers of both products have discontinued the production of those spot-ons.

The amitraz rinse has been shown to be an effective treatment option in many studies.^{94-98,100-112} This evidence for efficacy was confirmed by systematic reviews.⁴² Amitraz rinses require adequate skin contact for optimal efficacy. Therefore, it is recommended to clip the hair coat in medium- and long-haired dogs.¹¹³ The hair should be kept short throughout the treatment period. The rinse should be applied with a sponge and the skin

soaked thoroughly and allowed to dry without rinsing. Dogs should not get wet between rinses, to avoid washing off the amitraz. Gentle removal of crusts and surface debris with a shampoo is recommended before application of the amitraz rinse.¹¹³ Dogs should be lightly towel-dried after shampooing and water rinsing before the application of the amitraz rinse.

Rinses should be performed in a well-ventilated area and protective clothing should be worn by the handler, as adverse effects such as respiratory problems have been observed in humans.^{19,42} Care should be taken to avoid inappropriate ingestion or excessive exposure. In addition to respiratory adverse effects, many other adverse effects have been reported in humans associated with amitraz poisoning. A systematic review in humans analyzed 32 studies describing 310 cases of amitraz poisoning.¹¹⁴ The most commonly reported clinical features of amitraz poisoning were altered sensorium, miosis, hyperglycaemia, bradycardia, vomiting, respiratory failure, hypotension and hypothermia.¹¹⁴ Diabetic humans should avoid all contact with amitraz. Reported adverse effects of amitraz in dogs included depression, sleepiness, ataxia, pruritus, urticaria, oedema, skin irritations, polyphagia, polydipsia, hypotension, bradycardia, hyperglycaemia, vomiting and diarrhoea.^{19,42} Severe reactions or intoxications in dogs can be antagonized with yohimbine or atipamezole. Additional symptomatic treatment may be added. Smaller breed dogs, in particular toy-breed dogs, such as Pomeranians and Chihuahuas, are at increased risk for toxicity and deaths have been reported.¹¹⁵ Chihuahuas are specifically excluded on the label. Amitraz should be used with caution in very young, geriatric and/or debilitated animals. Because amitraz is an α -adrenergic agonist, sedating agents that also are α -adrenergic agonists (e.g. benzodiazepines, xylazine) should be avoided due to possible synergistic toxicity.¹⁹

The recommended concentration varies from 0.025% to 0.06% once weekly to every two weeks. Clinical efficacy increases with increasing concentration and shorter treatment intervals.^{104,105} Intensive protocols with daily rinsing of alternating body halves at a concentration of 0.125%¹⁰⁷ or weekly treatment with an amitraz concentration of 1.25%¹⁰⁴ have been reported in dogs not responding to conventional therapies. In the latter report, each time, dogs were treated once with atipamezole (0.1 mg/kg intramuscularly) followed by yohimbine (0.1 mg/kg) orally (p.o.) once daily for three days to minimize systemic adverse effects with each weekly treatment.¹⁰⁴ Treatment of pedal demodicosis with amitraz rinses may be especially problematic in wet environments because it is difficult to maintain sufficient amitraz on the pedal skin in these circumstances. Daily treatment of the paws¹⁹ or using other treatment modalities may be needed. As many as 20% of dogs with generalized demodicosis do not attain negative scraping results or experience a recurrence when treatment with amitraz is discontinued.¹⁰⁵ The success rate of amitraz rinses was reported to be lower in dogs with adult-onset demodicosis.⁴²

Combining amitraz with other miticidal therapies has been reported previously but is currently rarely used because of the high efficacy of other therapies. There is a

report of potentiated neurotoxicity in a dog treated with ivermectin and amitraz.¹¹³

Consensus Statement 9 Weekly amitraz rinses at 0.025–0.05% are effective for canine demodicosis; long-haired animals should be clipped.

7.3 Ivermectin

Ivermectin is derived from the fermentation of molecularly synthesized *Streptomyces avermitilis*.¹¹⁶ Since its introduction as a broad-spectrum parasiticide in 1981, it has become widely used in veterinary medicine. For almost two decades, ivermectin was the most commonly used macrocyclic lactone in the treatment of canine demodicosis. However, it is only approved in dogs for the prevention of the heartworm *Dirofilaria immitis* – all other applications are considered extra-label.¹¹⁷

Preliminary studies using ivermectin for the treatment of demodicosis evaluated various dosages and routes of administration. Initial results indicated that daily oral administration of ivermectin was the most efficacious protocol whilst weekly subcutaneous (s.c.) administration at 0.4 mg/kg¹⁰⁹ or use of a 0.5% ivermectin topical pour-on three times weekly¹¹⁸ yielded poor results. Several studies have examined the use of oral ivermectin at varying dosages with contrasting results. Oral administration at 350 μ g/kg⁷⁶ and 400 μ g/kg¹¹⁹ daily demonstrated poor efficacy with only 30% and 48% rates of cure, respectively. However, small sample size and concurrent administration of other drugs may have negatively impacted the results of these trials. By contrast, the cure rate was 85% in another study when ivermectin was administered at 300 μ g/kg p.o. daily,¹²⁰ similar results were achieved using 500–600 μ g/kg.^{121–123} The currently recommended protocols generally employ 300–600 μ g/kg p.o. once daily until four to eight weeks beyond parasitological cure.

Despite its frequent successful use in the treatment of demodicosis, it is unlikely that ivermectin will ever become labelled for this purpose due to its potential toxicity. Dogs treated with ivermectin should be closely monitored for potential neurotoxicity, especially ivermectin-sensitive breeds such as collie breeds, Australian shepherd dogs, Shetland and old English sheepdogs or dogs treated with high doses of ivermectin. Clinical signs of toxicosis may include mydriasis, lethargy, vomiting, ataxia, tremors and temporary blindness, which may rapidly progress to seizures, stupor, coma, respiratory failure and death.^{42,124,125} Mydriasis is typically the first clinical sign of ivermectin toxicity and the last to resolve. There is no specific antidote for ivermectin toxicosis. Depending on their severity, the clinical signs typically resolve within days to weeks following cessation of the drug along with supportive care. In the case of an acute oral overdose, repeated doses of activated charcoal may be administered in an effort to disrupt enterohepatic recirculation.¹¹⁷ Intravenous lipid emulsion therapy has been shown to be effective in the treatment of adverse reactions to all lipophilic drugs including ivermectin.¹²⁶ Its effect is thought to be due to the lipid sink mechanism whereby the drug is drawn out of the tissues and

sequestered into a lipid phase within the intravascular space, thereby decreasing CNS tissue concentrations.¹²⁶ Physostigmine, a parasympathomimetic alkaloid and reversible cholinesterase inhibitor, has been shown to cause short-term improvement in neurological signs but is not recommended for prolonged use due to its significant cholinergic effects and only temporary action.¹²⁵ Flumazenil, a gamma-aminobutyric acid (GABA)-antagonist, has been shown to reverse the effects of ivermectin in experimental models in rodents.^{125,127} However, its clinical efficacy in dogs has yet to be demonstrated.

Ivermectin toxicity can occur as a result of acute overdose, elevated serum concentration following long-term administration or associated with genetic susceptibility which is seen most commonly in herding breeds such as collie breeds, Australian shepherd dogs, Shetland and old English sheepdogs and their crosses but also has been recognized to occur in other breeds.^{124,128–130} Not uncommonly, this results in a severe and sometimes fatal idiosyncratic neurotoxicosis. Ivermectin-sensitivity occurs in individuals that carry a frame shift deletion mutation of the ABCB1 gene (formerly multi-drug resistance gene, *mdr1*), which is responsible for producing P-glycoprotein (P-gp), an ATP-dependent transmembrane transporter protein which plays an important role in the blood–brain barrier.¹²⁹ The deletion mutation causes P-gp synthesis to terminate prematurely resulting in severely truncated, nonfunctional P-gp molecules. Consequently, transport of certain drugs out of the central nervous system (CNS) is impaired, leading to accumulation of drug within the CNS to toxic levels.¹²⁹ Ivermectin is among the substrates for P-gp and therefore, individuals that are homozygous for this autosomal recessive gene demonstrate the ivermectin-sensitive phenotype. Dogs can be tested for the ABCB1-1Δ genotype before beginning ivermectin therapy through a number of laboratories.^{125,130} However, dogs without this defect also may show signs of toxicity.¹³¹

In ivermectin-sensitive individuals, toxicity may be apparent 4–12 h after oral administration.¹²⁵ Slow titration up to the therapeutic dose over several days is recommended when instituting ivermectin therapy in all breeds of dogs to enable close monitoring for adverse reactions and early identification of ivermectin-sensitive individuals.¹²⁴ A starting dose of 0.05 mg/kg on Day 1 is recommended, then 0.1 mg/kg on Day 2 followed by incremental doses of 0.1 mg/kg/day until the final dose is achieved.¹²⁴ Treatment should cease and an alternate therapy be considered if neurological signs develop during this titration period.

Owing to ivermectin's long half-life (80 ± 30 h),¹²⁶ serum concentrations rise over weeks until after perhaps six weeks a steady-state is reached. Subchronic ivermectin toxicity also has been reported following long-term therapy as serum drug concentrations accumulate to toxic levels.^{42,119} In a study of 28 dogs that developed subchronic toxicity while being treated for demodicosis with ivermectin or other macrocyclic lactones, only one dog was heterozygous and all others were homozygous for the normal ABCB1 gene.¹³¹ Interestingly, 10 dogs in this study were concurrently receiving one or more drugs that also are substrates of P-gp such as ketoconazole, ciclosporin or glucocorticoids. The concurrent use of

ivermectin with other P-gp substrates should be avoided whenever possible. In addition, use of spinosad-containing products should be avoided as mild to moderate ivermectin toxicosis has been reported when these drugs are used concurrently.¹³² Spinosad has been shown to be a potent inhibitor of canine P-gp which accounts for its impact on ivermectin pharmacokinetics.^{132,133} In Europe and in the USA, under the Animal Medicinal Drug Use Clarification Act (AMDUCA), off-label therapies should only be used in instances where a drug licensed for the purpose of treating demodicosis has either failed or is contra-indicated.

7.4 Milbemycin oxime

Milbemycin oxime is the fermentation product of *Streptomyces hygroscopicus aureolacrimosus*. It is approved in many countries as an endoparasiticide. In some countries, oral milbemycin oxime is licensed for the treatment of canine demodicosis at a dose of 0.5–2 mg/kg daily. In studies from the USA and Australia, a clearly higher success rate was seen with the higher dose of 1–2 mg/kg compared to 0.5–1 mg/kg p.o.^{15,134,135} However, these studies were conducted in referral practices with potentially more chronic and severely affected cases. By contrast, a Swedish study showed a good response with the low dose protocol,¹³⁶ possibly because most dogs in that study were diagnosed early in the disease and had not previously been treated with other miticides. Alternatively, a different genetic background of the dogs or different sensitivity of the mites to milbemycin oxime may have influenced the results. The success rate of milbemycin oxime was shown to be much lower in dogs with adult-onset demodicosis.^{15,135}

There seems to be a high safety margin with milbemycin oxime.⁴² It has been administered to rough collies at a dose of 2.5 mg/kg daily for 10 days with no adverse effects observed.¹³⁷ However, dogs homozygous for the ABCB1-1Δ (MDR-1) mutation developed ataxia with milbemycin oxime at a dose of only 1.5 mg/kg daily, although they tolerated the drug at 0.6 mg/kg/day.¹²⁸ In herding breeds, it is thus prudent to evaluate the ABCB1-1Δ (MDR-1) genotype and to use lower doses or increase the dose gradually in dogs homozygous for the ABCB1-1Δ (MDR-1) mutation similar to what has been recommended for oral ivermectin.¹²⁴

7.5 Moxidectin

Moxidectin, a macrocyclic lactone derived from the fermentation of *Streptomyces* spp., has demonstrated comparable efficacy to that of other macrocyclic lactones in the treatment of canine generalized demodicosis. Daily administration at 300–400 µg/kg p.o. yielded cure rates of 72–85%^{138–140} and 500 µg/kg administered every 72 h showed similar results.¹²¹ When oral administration (500 µg/kg) was compared to the subcutaneous route (500–1,000 µg/kg), each administered every 72 h, rates of cure were 75% and 86%, respectively. Adverse effects were reported in 10–37% of dogs in these studies,^{121,138–140} but were mostly mild and included emesis, salivation, anorexia, lethargy, dyspnoea and facial oedema. Because these occurred more frequently with subcutaneous administration,¹⁴⁰ the oral route is

preferable. The efficacy of moxidectin appears to be similar to that of ivermectin; although neurological signs such as mydriasis, tremor, ataxia and seizures have been reported with overdoses,¹²⁵ moxidectin seems to be better tolerated by ivermectin-sensitive individuals than is ivermectin.¹³⁹ Nevertheless, a gradual dose increase over several days similar to what is recommended for ivermectin¹²⁴ seems prudent to identify the few dogs intolerant to the drug, before adverse effects become severe and potentially fatal.⁴²

Topical application appears to be better tolerated than either of the aforementioned routes. A 2.5% preparation of moxidectin combined with 10% imidacloprid was well-tolerated even in ivermectin-sensitive breeds that were given three monthly applications of up to five times the recommended dose.¹⁴¹ When applied every two weeks, efficacy was greater in dogs with juvenile- versus adult-onset disease, similar to studies using other treatment protocols.⁷⁷ In a study comparing varying application rates of the moxidectin/imidacloprid spot-on, a significant dose-dependent effect was observed resulting in enhanced efficacy with more frequent application than once monthly.^{123,142} No adverse events occurred in the moxidectin/imidacloprid-treated dogs. By contrast, in the same study, three dogs became intoxicated while receiving daily ivermectin at 500 µg/kg p.o. Although ivermectin was more efficacious than moxidectin/imidacloprid in this study, weekly application of the latter yielded good clinical results and represents a safe therapeutic option.^{123,142} Follow-up data also revealed good long-term effects with no relapse of disease within one year of parasitological cure. Based on the demonstrated dose-dependent efficacy, this product has been registered for weekly use in dogs with demodicosis in many countries and should be considered in mild to moderate cases.

Further research is required to evaluate the impact of the topical moxidectin/imidacloprid preparation in the prevention of relapse of demodicosis following parasitological cure. One pilot study evaluated the response to once monthly treatment in twelve dogs with relapsing juvenile- and adult-onset generalized demodicosis following parasitological cure. All but one dog remained in remission during the 12 month trial.¹⁴³ Because this spot-on is commonly prescribed for young dogs as a monthly agent for the treatment and prevention of other parasitic diseases, its influence on the progression of localized demodicosis to the more generalized form should be evaluated. However, the high rate of spontaneous resolution of localized disease complicates interpretation of such studies.¹⁹

7.6 Doramectin

Doramectin is a longer-acting macrocyclic lactone that has been reported as a successful treatment for canine demodicosis.^{144–146} In the first study, 23 dogs were injected once weekly with 600 µg/kg s.c. for 5–23 weeks.¹⁴⁴ Ten of the dogs were cured, seven relapsed after 1–24 months (two of which responded to repeat doramectin treatment) and six were lost to follow-up. None of the animals in this study were reported to show any adverse effects with therapy. In a second study, doramectin was given orally to 29 dogs with

generalized demodicosis with good efficacy.¹⁴⁵ Ataxia as an adverse effect of doramectin therapy for demodicosis was seen in one golden retriever.¹⁴⁵ Another study involved 400 client-owned dogs treated with weekly doramectin injections (0.6 mg/kg s.c.), 232 of which successfully completed the protocol. Two hundred and twenty of these dogs (94.8%) achieved clinical remission with two consecutive negative skin scrapes collected two weeks apart. The time taken to achieve this remission ranged from four to 20 weeks (mean duration 7.1 weeks). Three dogs (1.3%) relapsed within a month of treatment cessation but all were successfully treated with a second round of injections. Ten (4.3%) were failures, with no detectable difference in mite numbers seen on follow-up skin scrapings (mean treatment duration 6.4 weeks). The treatment was well-tolerated and only two adverse reactions were seen, one was a local irritation reaction at the injection site and the other ataxia, both developing during therapy and resolved when therapy was withdrawn. Of 17 adult animals (older than four years), 47% had an underlying concurrent disease diagnosed. The efficacy was lower in this group and only 66.7% achieved remission in 6–8 weeks (mean duration 7.1 weeks).

In a further study, sixteen dogs were treated with 600 µg/kg doramectin s.c. once weekly and 13 dogs received 600 µg/kg doramectin p.o. twice weekly. The mean time to achieve negative skin scrapings was 13 and 12 weeks, respectively ($P = 0.955$). Adult-onset demodicosis affected five of 16 and two of 13 dogs, respectively ($P = 0.662$). The success rate for treatment was 13 of 16 (81%) of dogs receiving subcutaneous injections once weekly and 12 of 13 (92%) dogs receiving oral dosing twice weekly. ($P = 0.691$). Adverse effects were not observed in any dog. Oral administration of doramectin twice weekly does not achieve a more rapid resolution of canine generalized demodicosis than administration by subcutaneous injection once weekly, but treatment success was the same with both protocols.¹⁴⁷ Finally one report described using doramectin in a 2-week-old litter of nine pug dogs which were presented with pustular lesions covering several areas of the body. All puppies were safely and effectively treated with 0.6 mg/kg/week doramectin with clinical lesions resolved within four weeks and mite negative by eight weeks.¹⁴⁸ Overall this appears to be a well-tolerated and useful therapy for the treatment of canine generalized demodicosis.

Consensus Statement 10 Oral ivermectin at 0.3–0.6 mg/kg daily, moxidectin at 0.3–0.5 mg/kg daily, milbemycin oxime at 1.0–2.0 mg/kg daily and doramectin injected subcutaneously every week at 0.6 mg/kg are effective therapies for canine demodicosis, but an initial gradual dose increase is recommended for systemic moxidectin and ivermectin to identify dogs sensitive to toxicoses induced by those macrocyclic lactones. Topical moxidectin/imidacloprid should be considered for mild-moderate cases of canine demodicosis.

7.7 Isoxazolines

Recently, a new group of parasiticides also effective against canine demodicosis has been introduced to veterinary medicine.¹⁴⁹ These ectoparasiticides are isoxazolines and include fluralaner, sarolaner, afoxolaner and lotilaner. These molecules have been shown to target a binding site that inhibits insect and acarine ligand-gated chloride channels, in particular those gated by the neurotransmitter GABA, thereby blocking pre- and postsynaptic transfer of chloride ions across cell membranes.¹⁵⁰ Prolonged isoxazoline-induced hyperexcitation results in uncontrolled activity of the CNS and death of insects and acarines. The selective toxicity of isoxazolines between insects, acarines and mammals may be inferred by the differential sensitivity of the insects' and acarines' GABA receptors versus mammalian GABA receptors.^{151,152}

7.7.1 Fluralaner

Fluralaner (4-[5-(3,5-dichlorophenyl)-4,5-dihydro-5-(trifluoromethyl)-3-isoxazolyl]-2-methyl-N-[2-oxo-2-((2,2,2-trifluoroethyl)amino)ethyl]-benzamide) is a rapidly absorbed isoxazoline, that reaches maximum concentrations within 24 h and is quantifiable in plasma for up to 112 days after a single oral administration.¹⁵³ Absorption is increased when fluralaner is given with food;¹⁵⁴ it is predominantly excreted unchanged in the faeces by hepatic elimination.¹⁵³ It is administered orally every three months. The long interval between treatments may increase owner compliance and thus successful treatment outcome. Fluralaner can be used without additional risk for collie breeds and other sensitive herding breeds that have the MDR1 mutation.¹⁵⁵ Following intravenous administration fluralaner exhibits a relatively high apparent volume of distribution, a low plasma clearance, a long terminal half-life of 12–15 days, and a long mean residence time of 15–20 days, thereby demonstrating a long persistence of fluralaner in both dogs and cats.¹⁵⁶

Fluralaner every three months was compared to a spot-on containing imidacloprid/moxidectin administered once monthly.¹⁵⁷ A reduction of 99.8% and 98%, respectively, in mite numbers was achieved after 28 days. Scrapings were negative in all dogs treated with fluralaner after 56 days.¹⁵⁷ However, the dogs used in this study came from South Africa were probably not comparable to privately owned dogs in Europe or North America. In a larger clinical study, 163 dogs of various breeds with generalized demodicosis (63% with juvenile- and 37% with adult-onset of the disease) were treated with fluralaner once at a single dose of 25 mg/kg.¹⁵⁸ The majority of dogs (87%, all of the dogs with juvenile onset and most with adult-onset demodicosis) had negative skin scrapings after one month and all dogs were negative on scraping after two months. Adverse effects were not seen.¹⁵⁸ A further study that included 67 dogs also demonstrated that fluralaner when given at the recommended dose for flea and tick prevention was effective for the treatment of canine generalized demodicosis.¹⁵⁹ In 46 individuals with adult-onset demodicosis 63%, 85% and 100% cure rates were observed after two, three and four months, respectively. In 21 dogs diagnosed with juvenile-onset demodicosis in this same study, 81% and 100% cure rates were observed after two and three months, respectively.

Adverse reactions in fluralaner-treated dogs in studies evaluating flea and tick control were uncommon to rare. During a 12-week period, only four of 223 fluralaner-treated dogs (2.0%) had an adverse event, this was in all cases transient gastrointestinal-related signs including vomiting and anorexia.¹⁶⁰ In toxicity studies, administration of fluralaner at the highest recommended treatment dose (56 mg/kg p.o.) at eight-week intervals caused no clinical signs, the safety margin in healthy dogs 8 weeks or older and weighing ≥ 2 kg was more than five times the labelled dose.¹⁵⁵ Of 224 dogs participating in a 182 day field study, 7.1%, 6.7% and 4.9% showed emesis, decreased appetite and diarrhoea, respectively. Lethargy, polydipsia and flatulence were seen in 5.4%, 1.8% and 1.3% of the dogs, respectively.¹⁶¹

Fluralaner can be used without additional risk for collies and other sensitive herding breeds that have the MDR1 mutation.¹⁵⁵ No adverse events were observed subsequent to fluralaner treatment of ABCB1-1 Δ (–/–) Collies at three times the highest expected clinical dose. Fluralaner seems to be an effective, safe and convenient treatment option for all breeds of dogs with generalized demodicosis.^{157,158} However, due to anecdotal very rare neurological adverse effects, it is recommended in the package insert to use fluralaner with caution in dogs with pre-existing epilepsy.

7.7.2 Afoxolaner

Afoxolaner [1-Naphthalenecarboxamide, 4-(5-(3-chloro-5-(trifluoromethyl)phenyl)-4,5-dihydro-5-(trifluoromethyl)-3-isoxazolyl)-N-(2-oxo-2-((2,2,2-trifluoroethyl)amino)ethyl)] is one of the members of the isoxazoline family. In a variety of studies, afoxolaner was demonstrated to be a highly effective and safe form of flea and tick control.^{162–165}

Afoxolaner is a palatable beef-flavoured product that can be given with or without food. After oral administration to dogs, it is rapidly absorbed into the systemic circulation, where the drug becomes active. Afoxolaner is highly protein bound (>99%) and the unbound fraction distributes moderately into tissues.¹⁶⁶ It is slowly eliminated from the body via biliary excretion of free afoxolaner and via hepatic metabolism and subsequent biliary and renal clearance of afoxolaner metabolites. This slow clearance gives afoxolaner a long half-life in dogs and sustained ectoparasitic activity. In an oral bioavailability study, afoxolaner was rapidly absorbed ($T_{max} = 2–4$ h), achieved a maximum plasma concentration (C_{max}) of $1,655 \pm 332$ ng/mL, demonstrated a bioavailability of 73.9% and exhibited a terminal plasma half-life of 15 days.¹⁶⁶ Company-generated study data showed no differences in pharmacokinetics in fed or fasted dogs supporting that it can be given without food.

Adverse reactions in flea and tick studies are rare. In a 90-day US field study of 415 dogs, vomiting was seen in 17 (4.1%), dry flaky skin in 13 (3.1%), diarrhoea without blood in 13 (3.1%) and lethargy in seven (1.7%).¹⁶⁷ Only five dogs showed anorexia during the study and two of those dogs experienced anorexia with the first dose but not subsequent doses. Three dogs in that field study had a history of seizures. One dog experienced a seizure on the same day after receiving first and second dosing and a third seizure one week after the third dosing but

completed the study. One other dog with a history of seizures had one seizure 19 days after the third dose. The third dog with a history of seizures had no seizures during the study trial.¹⁶⁷ The safety profile of afoxolaner was further evaluated in two studies in 8-week-old beagle dogs.¹⁶⁴ In the first study, 32 beagle dogs were randomly assigned to receive 1×, 3× or 5× the maximum exposure dose (6.3 mg/kg). Treatments were administered at three dose intervals of one month (days 0, 28 and 56) followed by three fortnightly dose intervals (days 84, 98 and 112). Physical examinations, and blood collections for clinical pathological analysis and afoxolaner plasma concentrations, were performed throughout the study. No afoxolaner-related changes were observed in growth, physical variables, clinical pathological variables or tissues examined histologically. No clinically or statistically significant health abnormalities related to the administration of afoxolaner were observed. Vomiting and diarrhoea were observed sporadically across all groups including the controls.¹⁶⁴ In the second study, afoxolaner was combined with milbemycin and the same protocol was repeated as performed in the first study. No treatment-related changes were observed in any of the examinations described above. Vomiting and diarrhoea were observed sporadically across all groups including the control group.¹⁶⁸ In the USA, afoxolaner is approved to be given to 8-week-old puppies. The safety of afoxolaner in breeding, pregnant and lactating dogs has not been evaluated.

Afoxolaner is registered for treatment of canine demodicosis in Europe and has been shown to be highly effective for treatment of demodicosis in case reports^{169–171} and one controlled study.¹⁷² The controlled published report looked at eight dogs diagnosed with generalized demodicosis and compared the efficacy with a topical combination of imidacloprid/moxidectin. Afoxolaner was administered at the recommended dose (≥ 2.5 mg/kg) on days 0, 14, 28 and 56, and the topical combination of imidacloprid/moxidectin was given at the same intervals at the recommended concentration. Clinical examinations and deep skin scrapings were performed every month to evaluate the effect on mite numbers and the resolution of clinical signs. The percentage reductions of mite counts were 99.2%, 99.9% and 100% on days 28, 56 and 84, respectively, in the afoxolaner-treated group, compared to 89.8%, 85.2% and 86.6% on days 28, 56 and 84 in the imidacloprid/moxidectin-group. Mite reductions were significantly higher on days 28, 56 and 84 in the afoxolaner-treated group compared to the imidacloprid/moxidectin treated group.¹⁷²

In a large series of clinical case evaluations at a referral dermatology practice, 102 cases of generalized demodicosis were treated with excellent results. Of the 102 cases, 68 were dogs with adult-onset demodicosis. The product was administered at 2.5 mg/kg p.o., initially used every two weeks in the first 10 dogs. With the high degree of efficacy seen in those dogs, the dosage was reduced to monthly in the remaining cases. Ninety per cent of the cases were negative after two months of treatment, the remaining dogs after three months. The only dog needing administration every two weeks was on immunosuppressive therapy for pemphigus foliaceus that became mite-positive when the interval was increased to

four weeks, but remained mite-negative when afoxolaner was administered every two weeks.¹⁷⁰ In a further study, 50 dogs with generalized demodicosis were treated with afoxolaner alone (Nexgard[®]) or combined with milbemycin (Nexgard Spectra[®]) with 2.5–2.7 mg/kg once monthly and the number of mites on skin scrapings was reduced by 87.6%, 96.5% and 98.1% on days 28, 56 and 84, respectively, and 36 of 50 dogs had negative skin scrapings after three months.¹⁷³ A more recent study looked at afoxolaner combined with milbemycin (Nexgard Spectra[®]) at the dosage of 2.5–6.3 mg/kg p.o. every four weeks in dogs with juvenile-onset ($n = 4$) and adult-onset ($n = 11$) generalized demodicosis with a variety of clinical lesions. The rate of decrease in mite counts was 91.2%, 99.8% and 99.9% on days 28, 56 and 84, respectively.¹⁷¹ Based on these data, afoxolaner seems to be an effective, safe and convenient treatment option for dogs with generalized demodicosis.

7.7.3 Sarolaner

Sarolaner [1-(5'-((5S)-5-(3,5-dichloro-4-fluorophenyl)-5-(trifluoromethyl)-4,5-dihydroisoxazol-3-yl)-3'-H-spiro[azetidine-3,1'-(2-benzofuran)-1-yl]-2-(methylsulfonyl) ethanone)] was discovered through a targeted synthesis and screening programme, and was selected for development on the basis of structural uniqueness, potency, mammalian safety and pharmacokinetic suitability.¹⁷⁴ This isoxazoline can be used safely for puppies from eight weeks of age.¹⁷⁵ In an initial *in vivo* study in dogs, sarolaner demonstrated robust efficacy ($\geq 99.8\%$) for 35 days against both fleas and adult ticks.¹⁷⁵ Sarolaner chewable tablets are generally well-tolerated with rare treatment-related adverse reactions. The majority of observed adverse events are typical of those commonly seen in the general dog population. In a 90 day study, vomiting was observed in 10 of 315 dogs (3.5%) and lethargy in eight dogs (2.5%).¹⁷⁶ Sarolaner is currently authorized as chewable tablet with indications for the treatment of fleas, ticks, demodicosis and ear mites in dogs.

In one study, 16 dogs with generalized demodicosis were treated either with monthly oral sarolaner or with a weekly spot-on containing imidacloprid and moxidectin.¹⁷⁷ The sarolaner-treated dogs and the dogs treated with the spot-on had a reduction of over 99% and 96% in mite numbers after one month and negative scrapings after one month and after 11 weeks, respectively.¹⁷⁷ In addition, the *Demodex*-infested dogs showed a marked improvement in their clinical signs. There were no treatment-related adverse events observed. A subsequent noninferiority study compared the same two products in 81 client-owned dogs.¹⁷⁸ Parasitological cure in dogs treated with sarolaner was achieved in 93% after three months and 100% after five months, confirming the efficacy of sarolaner against canine generalized demodicosis.

Consensus Statement 11 A number of studies have evaluated the efficacy of isoxazolines for canine demodicosis in pet dogs. The published data are very encouraging and make this drug class an excellent treatment option for dogs with demodicosis.

7.7.4 Lotilaner

Lotilaner (Credelio™, Elanco) is the newest isoxazoline molecule and was evaluated against *Demodex* spp. in 10 naturally infested dogs with generalized demodicosis.¹⁷⁹ Dogs were treated with 20 mg/kg p.o. on days 0, 28 and 56. The pre-treatment mite counts based on skin scrapings performed at five different sites were reduced by >99.9% ($P < 0.0001$) up to 56 days after the first and second monthly doses. No live mites were detected in any dog after Day 56 and including Day 84 post-treatment,¹⁷⁹ indicating that this drug may also be effective against canine demodicosis.

7.8 Other drugs

Various other drugs have been used to treat generalized demodicosis. As described above, an immune aberration seems to contribute to the development of generalized demodicosis.¹⁸⁰ Thus, it seems logical that immunomodulatory agents may be beneficial for dogs with demodicosis and a number of those agents were evaluated in several studies.

A mycobacterial cell wall component, muramyl dipeptide, was injected at 0.2 mg/kg s.c. weekly in dogs with generalized demodicosis either as monotherapy or in combination with amitraz at two different concentrations (0.025% and 0.05% twice weekly) and compared to therapy with amitraz alone at 0.025% twice weekly.¹⁸¹ Remission was achieved in all dogs. The study numbers were very small (two dogs per treatment group) and there was no follow-up period, thus it is difficult to ascertain if the muramyl dipeptide was of any benefit. Muramyl dipeptide also was shown in a separate study to increase the lymphocyte response to mitogens in eight dogs with demodicosis, without reaching the comparative values of healthy dogs.²¹ Adverse effects were not mentioned.

Levamisole at a dose from 3 to 10 mg/kg given at different intervals was used in two studies,^{180,182} which showed a positive effect on lymphocyte proliferation assays, but did not improve efficacy based on clinical or parasitological resolution of demodicosis.

In another study, 16 dogs with generalized demodicosis were treated either with amitraz rinses at 0.0375% every five days alone or in combination with 2 mL of inactivated *Parapox virus suis* s.c. on days 0, 2 and 9.¹⁸³ The dogs receiving combination therapy achieved remission within 85 days compared to 104 days in the control group ($P < 0.05$), although a power analysis was not presented. To the best of the authors' knowledge, this is the first randomized trial showing a beneficial effect of an immunostimulant as treatment for canine demodicosis.

Thirty-six dogs with generalized demodicosis were treated with 1,000 mg of vitamin E daily, weekly amitraz rinses at 0.05% or a combination of both therapies.¹⁸⁴ All dogs went into remission, the dogs on combination therapy had the shortest time until remission (7.1 weeks versus 7.3 weeks with amitraz only and 8.5 weeks with vitamin E only) but a statistical evaluation was not performed. Compared to a control group, affected dogs had lower serum vitamin E concentrations. However, it was not known if inadequate dietary intake of vitamin E at the beginning of the study or the disease caused this difference. When the mean serum vitamin E concentration

was compared among dogs with pyoderma, generalized demodicosis and normal dogs, no significant differences were found between groups.¹⁸⁵

Lufenuron is a chitin synthesis inhibitor. As chitin is found in the shells and exoskeletons of all life stages of *Demodex* spp.¹⁸⁶ it was proposed that this compound might interrupt the life cycle of the *Demodex* mite. However, lufenuron at mean doses of up to 15.8 mg/kg three times weekly for 2–3 months did not lead to improvement of canine demodicosis.¹⁸⁷

Three dogs with generalized demodicosis were sprayed weekly with a deltamethrin spray at 0.005%. After three weekly applications, there was no difference in clinical signs or numbers of mites on skin scrapings.¹¹¹ Deltamethrin at 12.5% was used in another report and compared with an indigenous preparation containing extracts of *Mallotus philippensis*, *Oleum pinus*, *Oleum terebinth* and *Sulphur sublimatum*. Topicals were applied twice daily until skin scrapings were negative, which took seven days in the group treated with the indigenous preparation and 11 days for deltamethrin.¹⁸⁸ Dogs had to be restrained for 1 h after the topical application to prevent excessive licking. Skin scrapings were still negative in all dogs one month after cessation of therapy.

Homeopathic preparations containing Sulphur 200, Heparsulphuris 200 or Psorinum 200 were given orally at five drops daily for five weeks to three groups of six puppies experimentally infected with *Demodex canis*.¹⁸⁹ The post-treatment mean demodicosis indices were lower in the groups treated with Sulphur 200 and Psorinum 200 compared with the group treated with Heparsulphuris 200 and a control group, but neither complete clinical nor microscopic resolution could be achieved. A herbal preparation containing extracts of *Cedrus deodara*, *Azadirachta indica* and *Embelia ribes* was sprayed on lesions of 14 juvenile dogs with apparent generalized demodicosis.¹⁹⁰ Dogs were re-evaluated after 24 h and if skin scrapings were still positive for *D. canis*, dogs were retreated once. Subsequent weekly skin scrapings for six weeks were negative in all dogs.

Closantel ((N 9–5-chloro-4-(4-chlorophenyl) cyanomethyl)-2-methylphenyl)-2-hydroxyl 3,5 diodobenzamide) is an anthelmintic of the salicylanilide family and was used to treat nine juvenile dogs with generalized demodicosis at a dose of 5 mg/kg s.c. for the first injection and 2.5 mg/kg s.c. for subsequent weekly injections.¹⁹¹ All dogs improved, but only six dogs went into remission based on assessment of skin scrapings, after six injections. A follow-up period was not specified.

Overall, for almost all of those drugs there is insufficient evidence to be recommended as treatment of canine generalized demodicosis, either due to low numbers of patients in the studies, unclear methods, insufficient efficacy or prominent adverse effects.⁴² There is some evidence for efficacy of inactivated *Parapox virus suis* subcutaneously as a concurrent treatment to amitraz.¹⁸³

7.9 Treatment of feline demodicosis

A number of drugs have been used to treat feline demodicosis, including organophosphate baths,^{192–195} rotenone,^{192,196} lime sulfur dips,^{18,72,73,197,198} amitraz rinses,^{72,199–201} ivermectin orally and by injection,⁷²

selamectin,⁷² milbemycin oxime¹⁶ and a moxidectin/imidacloprid spot-on.²⁰²

The two treatments most frequently reported as successful are lime sulfur dips and amitraz rinses. Lime sulfur dips were used at 2% every 5–7 days^{72,73,197,198,201} and were successful in 22 of 24 cats. Adverse effects were not seen. Amitraz rinses were typically used at a concentration of 0.0125%^{72,201} to 0.025%¹⁹⁹ up to 0.1%²⁰⁰ weekly and 12 of 14 cats responded to treatment. However, both treatments are not always well-tolerated by the affected cats. In a case series, eight of 13 cats in one household showed pruritic skin disease and skin scrapings were positive for *D. gatoi* in two of those cats. Weekly administration of a spot-on containing moxidectin/imidacloprid for 10 weeks was well-tolerated and pruritus resolved in all cats following treatment.²⁰² Thus, at least for *D. gatoi*, this spot-on may be a more convenient efficacious therapy.

Oral fluralaner has been used in a cat with demodicosis,²⁰³ leading to rapid resolution of clinical signs and negative skin scrapings.

Consensus Statement 12 Demodicosis in cats may be treated with weekly lime sulfur dips at a concentration of 2% or amitraz baths at a concentration of 0.0125%. An easier alternative may be weekly administration of a spot-on containing moxidectin/imidacloprid.

8 Prognosis and future outlook

With the advent and widespread use of isoxazoline therapy for flea and tick control, the future incidence of canine demodicosis could be impacted. How prominent this effect will be remains to be seen in the coming years. Anecdotally, treatment of 15 breeding bitches with 25 mg/kg fluralaner 10 days prior to the scheduled mating and three months later with a second dose, resulted in a marked reduction in the numbers of puppies breaking out with demodicosis compared to the previous consistent production of litters developing the disease.¹⁷⁷ In this trial, all bitches were treated with 25 mg/kg fluralaner 10 days before the scheduled mating and three months later with a second dose. All 15 bitches included in the study gave birth to litters of healthy puppies and 14 of those 15 litters did not develop demodicosis in the first 12 months, and two puppies of one litter developed localized demodicosis only.¹⁷⁰ The obtained result indicates a high efficiency of fluralaner not only as a treatment, but also as a preventative strategy in cases of breed-predisposed, generalized, juvenile onset canine demodicosis. Although these results are impressive, isoxazoline therapy should not replace the need for withholding affected and carrier dogs from breeding programmes.

There also is concern about the possible impact of isoxazoline therapy on normal canine cutaneous *Demodex* populations. *Demodex* mites are considered part of the microbiota of most mammals, including dogs. Under normal circumstances, they appear to live as commensals, feeding on their host's sebum and are only opportunistically pathogenic. Similar to bacterial flora found on the

skin, in humans follicular mites have been shown to contain immune-reactive lipase,²⁰⁴ which can produce free fatty acids from sebum triglycerides. Therefore, the mites could play a role in the defence of the skin against pathogenic bacteria, particularly against *Staphylococcus aureus* and *Streptococcus pyogenes*.²⁰⁵

The investigation of the normal cutaneous *Demodex* populations has been, until recently, elusive due to the low number of individual mites present on healthy dogs. The development of PCR techniques targeting *Demodex*-DNA in skin samples has allowed advancement of the study of *Demodex* populations.²⁰⁶ A previous study using a real-time PCR (RT-PCR) for *D. canis* detected *Demodex*-DNA in approximately 18% of healthy dogs after sampling hairs from two to five body sites.⁷ Direct proportionality between the number of positive dogs and the number of sampled sites and hairs was demonstrated clearly, as positive results increased to 100% when the number of sampled sites increased to 20.⁷ Another study investigated whether healthy dogs treated with the isoxazolines afoxolaner and fluralaner at the labelled dose for flea and tick prevention would maintain a normal population of *Demodex* mites as part of their cutaneous microbiota. The study demonstrated that after 30 and 90 days of treatment, healthy dogs still had *Demodex* mites similar to the population of healthy dogs not receiving these treatments.²⁰⁷ However, PCR also will detect antigen from dead mites, the duration of the study was only three months and, to the best of the authors' knowledge, the maximum time to eliminate dead mites from the follicle is not known although the interfollicular epidermal turnover is faster than three months. These data may suggest that dogs receiving isoxazoline treatment maintain *Demodex* populations as part of their cutaneous microbiota, despite the apparent ability of these medications to resolve clinical demodicosis. To date, no studies have been performed to detect *Demodex*-DNA post-treatment in dogs with demodicosis. Isoxazolines may not affect *Demodex* mites in normal dogs to the same degree or may have no effect at all on normal mite populations in unaffected dogs. More studies of longer duration are needed to characterize the response of the *Demodex* populations in dogs with clinical disease to isoxazolines and in comparison to other treatments for demodicosis.

Currently the isoxazoline derivatives have shown impressive results in controlling demodicosis and are likely to be the mainstay therapy for many years to come. The development of resistance is less likely to occur due to their selective inhibition of insect and acarid GABACs and GluCs. This novel binding site is key to the innovative activity profile, which bypasses the critical cross-resistance observed in other noncompetitive antagonists²⁰⁸ and will likely slow development of resistance to this class of molecules. A combination product combining afoxolaner and milbemycin oxime has been released in Europe for flea, tick, nematode infestation and heartworm prevention.¹⁷⁷ No studies have been reported to date regarding demodicosis treatment with this product. However, the combined molecules of afoxolaner and milbemycin oxime could have additive effects, as both have efficacy for *Demodex* mites as sole molecules. In

view of these developments, further derivatives and combinations are likely to be approved and more treatment options will likely become available in the future.

Acknowledgement

The authors would like to thank the World Association for Veterinary Dermatology (WAVD) for supporting this initiative, the many colleagues that published studies evaluating demodicosis in various species and its treatments and thus indirectly contributed to this manuscript, and Sonya Bettenay for her input on the manuscript.

Author contributions

Ralf S. Mueller wrote the introduction, the sections about the pathogenesis, general treatment considerations, lotilaner, miscellaneous drugs and treatment of feline demodicosis, collected the contributions of the other authors, and edited, formatted and finalized the manuscript; Emmanuel Bensignor wrote the sections on diagnosis and milbemycin oxime; Joanna Karaś-Tęcza wrote the sections on breeding considerations, fluralaner and sarolaner; Tara Paterson wrote the sections about moxidectin and ivermectin; Michael A. Shipstone wrote the sections about clinical signs and doramectin; and Wayne Rosenkrantz initiated these clinical consensus guidelines and contributed the sections on amitraz, afoxolaner, lotilaner and the future outlook.

References

- Moriello KA, Coyner K, Paterson S et al. Diagnosis and treatment of dermatophytosis in dogs and cats: Clinical Consensus Guidelines of the World Association for Veterinary Dermatology. *Vet Dermatol* 2017; 28: 266–e268.
- Morris DO, Loeffler A, Davis MF et al. Recommendations for approaches to meticillin-resistant staphylococcal infections of small animals: diagnosis, therapeutic considerations and preventative measures: Clinical Consensus Guidelines of the World Association for Veterinary Dermatology. *Vet Dermatol* 2017; 28: 304–e369.
- Sischo WM, Ihrke PJ, Franti CE. Regional distribution of ten common skin diseases in dogs. *J Am Vet Med Assoc* 1989; 195: 752–756.
- Scott DW, Paradis M. A survey of canine and feline skin disorders seen in a university practice: Small Animal Clinic, University of Montreal, Saint-Hyacinthe, Quebec (1987–1988). *Can Vet J* 1990; 31: 830–835.
- Lacey N, Kavanagh K, Tseng SC. Under the lash: Demodex mites in human diseases. *Biochem (Lond)* 2009; 31: 2–6.
- Nutting WB. Hair follicle mites (*Demodex* spp.) of medical and veterinary concern. *Cornell Vet* 1976; 66: 214–231.
- Ravera I, Altet L, Francino O et al. Small Demodex populations colonize most parts of the skin of healthy dogs. *Vet Dermatol* 2013; 24: 168–172.e37.
- Silbermayr K, Horvath-Ungerboeck C, Eigner B et al. Phylogenetic relationships and new genetic tools for the detection and discrimination of the three feline Demodex mites. *Parasitol Res* 2015; 114: 747–752.
- Tani K, Une S, Hasegawa A et al. Infestivity of *Demodex canis* to hamster skin engrafted onto SCID mice. *J Vet Med Sci* 2005; 67: 445–448.
- Jekl V, Hauptman K, Jeklova E et al. Demodicosis in nine prairie dogs (*Cynomys ludovicianus*). *Vet Dermatol* 2006; 17: 280–283.
- Greve JH, Gaafar SM. Natural transmission of *Demodex canis* in dogs. *J Am Vet Med Assoc* 1966; 148: 1,043–1,045.
- Bernstein JA, Frank LA, Kania SA. PCR amplification and DNA sequence identification of an unusual morphological form of *Demodex cati* in a cat. *Vet Dermatol* 2014; 25: 487–e80.
- Lowenstein C, Beck W, Bessmann K et al. Feline demodicosis caused by concurrent infestation with *Demodex cati* and an unnamed species of mite. *Vet Rec* 2005; 157: 290–292.
- Duclos DD, Jeffers JG, Shanley KJ. Prognosis for treatment of adult-onset demodicosis in dogs: 34 cases (1979–1990). *J Am Vet Med Assoc* 1994; 204: 616–619.
- Garfield RA, Lloyd R. The use of oral milbemycin oxime (Interceptor) in the treatment of chronic generalized canine demodicosis. *Vet Dermatol* 1992; 3: 231–235.
- Bizikova P, Linder KE, Olivry T. Fipronil-amitraz-S-methoprene-triggered pemphigus foliaceus in 21 dogs: clinical, histological and immunological characteristics. *Vet Dermatol* 2014; 25: 103–111, e29–30.
- Ivy SP, Mackall CL, Gore L et al. Demodicidosis in childhood acute lymphoblastic leukemia; an opportunistic infection occurring with immunosuppression. *J Pediatr* 1995; 127: 751–754.
- Chalmers S, Schick RO, Jeffers J. Demodicosis in two cats seropositive for feline immunodeficiency virus. *J Am Vet Med Assoc* 1989; 194: 256–257.
- Miller WH Jr, Griffin CE, Campbell KL. *Muller and Kirk's Small Animal Dermatology*, 7th edition. St Louis, MO: Elsevier Mosby, 2013; 304–315.
- Hirsh DC, Baker BB, Wiger N et al. Suppression of in vitro lymphocyte transformation by serum from dogs with generalized demodicosis. *Am J Vet Res* 1975; 36: 1,591–1,595.
- Kraiss A. [In German: Proliferating ability of the lymphocytes of demodectic dogs during immune cell-stimulating therapy]. *Tierarztl Prax* 1987; 15: 63–66.
- Owen LN. Demodectic mange in dogs immunosuppressed with antilymphocyte serum. *Transplantation* 1972; 13: 616–617.
- Ferrer L, Ravera I, Silbermayr K. Immunology and pathogenesis of canine demodicosis. *Vet Dermatol* 2014; 25: 427–e65.
- Souza CP, Schissler JR, Contreras ET et al. Evaluation of immunological parameters in pit bull terrier-type dogs with juvenile onset generalized demodicosis and age-matched healthy pit bull terrier-type dogs. *Vet Dermatol* 2018; 29: 482–e162.
- Tani K, Morimoto M, Hayashi T et al. Evaluation of cytokine messenger RNA expression in peripheral blood mononuclear cells from dogs with canine demodicosis. *J Vet Med Sci* 2002; 64: 513–518.
- Gasparetto ND, Almeida A, Nakazato L et al. Density measurement of *Demodex canis* by qPCR and analysis of serum cytokine levels in dogs with different clinical forms of demodicosis. *Vet Parasitol* 2018; 257: 1–4.
- Felix AO, Guiot EG, Stein M et al. Comparison of systemic interleukin 10 concentrations in healthy dogs and those suffering from recurring and first time *Demodex canis* infestations. *Vet Parasitol* 2013; 193: 312–315.
- Kumari P, Nigam R, Singh A et al. *Demodex canis* regulates cholinergic system mediated immunosuppressive pathways in canine demodicosis. *Parasitology* 2017; 144: 1,412–1,416.
- Singh SK, Dimri U, Sharma MC et al. Determination of CD4+ and CD8+ T cells in the peripheral blood of dogs with demodicosis. *Parasitology* 2010; 137: 1,921–1,924.
- Caswell JL, Yager JA, Parker WM et al. A prospective study of the immunophenotype and temporal changes in the histologic lesions of canine demodicosis. *Vet Pathol* 1997; 34: 279–287.
- Huisinga M, Failing K, Reinacher M. MHC class II expression by follicular keratinocytes in canine demodicosis—an immunohistochemical study. *Vet Immunol Immunopathol* 2007; 118: 210–220.
- Caswell JL, Yager JA, Barta JR et al. Establishment of *Demodex canis* on canine skin engrafted onto scid-beige mice. *J Parasitol* 1996; 82: 911–915.

33. Liu Q, Arseculeratne C, Liu Z et al. Simultaneous deficiency in CD28 and STAT6 results in chronic ectoparasite-induced inflammatory skin disease. *Infect Immun* 2004; 72: 3,706–3,715.
34. Linder KE, Kunkle GA, Parker WM et al. Application of the skin graft mouse model in veterinary dermatology research: modeling canine demodicosis. In: Thoday KL, Foil CS, Bond R, eds. *Advances in Veterinary Dermatology*, volume 4. Oxford: Blackwell Science; 2002:76–84.
35. Kumari P, Nigam R, Choudhury S et al. *Demodex canis* targets TLRs to evade host immunity and induce canine demodicosis. *Parasite Immunol* 2018; 40: e12509.
36. Barta O, Waltman C, Oyekan PP et al. Lymphocyte transformation suppression caused by pyoderma—failure to demonstrate it in uncomplicated demodectic mange. *Comp Immunol Microbiol Infect Dis* 1983; 6: 9–18.
37. Toman M, Svoboda M, Rybnicek J et al. Immunosuppression in dogs with pyoderma and/or demodicosis. *Vet Med (Praha)* 1997; 42: 299–306.
38. Barriga OO, al-Khalidi NW, Martin S et al. Evidence of immunosuppression by *Demodex canis*. *Vet Immunol Immunopathol* 1992; 32: 37–46.
39. Paulik S, Mojzisojova J, Bajova V et al. Evaluation of canine lymphocyte blastogenesis prior and after in vitro suppression by dog demodicosis serum using ethidium bromide fluorescence assay. *Vet Med (Praha)* 1996; 41: 7–12.
40. Paulik S, Mojzisojova J, Bajova V et al. Lymphocyte blastogenesis to concanavalin A in dogs with localized demodicosis according to duration of clinical disease. *Vet Med (Praha)* 1996; 41: 245–249.
41. Dimri U, Ranjan R, Kumar N et al. Changes in oxidative stress indices, zinc and copper concentrations in blood in canine demodicosis. *Vet Parasitol* 2008; 154: 98–102.
42. Mueller RS. Treatment protocols for demodicosis: an evidence-based review. *Vet Dermatol* 2004; 15: 75–89.
43. Mozos E, Perez J, Day MJ et al. Leishmaniosis and generalized demodicosis in three dogs: a clinicopathological and immunohistochemical study. *J Comp Pathol* 1999; 120: 257–268.
44. Huang HP, Lien YH. Treatment of canine generalized demodicosis associated with hyperadrenocorticism with spot-on moxidectin and imidacloprid. *Acta Vet Scand* 2013; 55: 40.
45. Tarello W. Remission of clinical signs of adult-onset generalized demodicosis after treatment for concurrent babesiosis and/or granulocytic ehrlichiosis in dogs. *Parasite* 2007; 14: 339–341.
46. Bowden DG, Outerbridge CA, Kissel MB et al. Canine demodicosis: a retrospective study of a veterinary hospital population in California, USA (2000–2016). *Vet Dermatol* 2018; 29: 19–e10.
47. Pinsenschaum L, Heung Lam C, Weber K et al. Is there a correlation between canine adult-onset demodicosis and other diseases? *Vet Rec* 2019; <https://doi.org/10.1136/vr.105388>
48. Taffin ER, Casaert S, Claerebout E et al. Morphological variability of *Demodex cati* in a feline immunodeficiency virus-positive cat. *J Am Vet Med Assoc* 2016; 249: 1,308–1,312.
49. Neel JA, Tarigo J, Tater KC et al. Deep and superficial skin scrapings from a feline immunodeficiency virus-positive cat. *Vet Clin Pathol* 2007; 36: 101–104.
50. Vogelnest LJ. Cutaneous xanthomas with concurrent demodicosis and dermatophytosis in a cat. *Aust Vet J* 2001; 79: 470–475.
51. White SD, Carpenter JL, Moore FM et al. Generalized demodicosis associated with diabetes mellitus in two cats. *J Am Vet Med Assoc* 1987; 191: 448–450.
52. Bensignor E, Carlotti DN. Epidermoid carcinoma in situ associated with localised demodicosis in a cat. *Prat Med Chirurg Anim Comp* 2000; 35: 559–562.
53. Guaguere E, Olivry T, Delverdier-Poujade A et al. *Demodex cati* infestation in association with feline cutaneous squamous cell carcinoma in situ: a report of five cases. *Vet Dermatol* 1999; 10: 61–67.
54. Mumcuoglu KY, Akilov OE. The role of HLA A2 and Cw2 in the pathogenesis of human demodicosis. *Dermatology* 2005; 210: 109–114.
55. Plant JD, Lund EM, Yang M. A case-control study of the risk factors for canine juvenile-onset generalized demodicosis in the USA. *Vet Dermatol* 2011; 22: 95–99.
56. It V, Barrientos L, Lopez Gappa J et al. Association of canine juvenile generalized demodicosis with the dog leukocyte antigen system. *Tissue Antigens* 2010; 76: 67–70.
57. Hillier A, Desch CE. Large-bodied *Demodex* mite infestation in 4 dogs. *J Am Vet Med Assoc* 2002; 220(623–627): 613.
58. Mueller RS, Bettenay SV. An unusual presentation of generalised demodicosis caused by a long-bodied demodex mite in a Lakeland Terrier. *Aust Vet Pract* 1999; 29: 128–131.
59. Ordeix L, Bardagi M, Scarampella F et al. *Demodex injai* infestation and dorsal greasy skin and hair in eight wirehaired fox terrier dogs. *Vet Dermatol* 2009; 20: 267–272.
60. Robson DC, Burton GG, Bassett R et al. Eight cases of demodicosis caused by a long-bodied *Demodex* species (1997–2002). *Aust Vet Pract* 2003; 33: 64–72.
61. Saridomichelakis M, Koutinas A, Papadogiannakis E et al. Adult-onset demodicosis in two dogs due to *Demodex canis* and a short-tailed demodectic mite. *J Small Anim Pract* 1999; 40: 529–532.
62. Sivajothi S, Sudhakar Reddy B, Rayulu VC. Demodicosis caused by *Demodex canis* and *Demodex cornei* in dogs. *J Parasit Dis* 2015; 39: 673–676.
63. Chesney CJ. Short form of *Demodex* species mite in the dog: occurrence and measurements. *J Small Anim Pract* 1999; 40: 58–61.
64. Tamura Y, Kawamura Y, Inoue I et al. Scanning electron microscopy description of a new species of *Demodex canis* spp. *Vet Dermatol* 2001; 12: 275–278.
65. Izdebska JN, Rolbiecki L. The status of *Demodex cornei*: description of the species and developmental stages, and data on demodecid mites in the domestic dog *Canis lupus familiaris*. *Med Vet Entomol* 2018; 32: 346–357.
66. de Rojas M, Riazco C, Callejon C et al. Molecular study on three morphotypes of *Demodex* mites (Acarina: Demodicidae) from dogs. *Parasitol Res* 2012; 111: 2,165–2,172.
67. Sastre N, Ravera I, Ferreira D et al. Development of a PCR technique specific for *Demodex injai* in biological specimens. *Parasitol Res* 2013; 112: 3,369–3,372.
68. Fiorucci G, Fogel F, Paradis M. *Demodex cornei*: podrían ser ácaros *Demodex canis* transformados, moribundos o muertos. *Rev Vet Argentina* 2015; 22: 1–14.
69. Desch C, Nutting WB. *Demodex cati* Hirst 1919: a redescription. *Cornell Vet* 1979; 69: 280–285.
70. Desch CE Jr, Stewart TB. *Demodex gatoi*: new species of hair follicle mite (Acari: Demodicidae) from the domestic cat (Carnivora: Felidae). *J Med Entomol* 1999; 36: 167–170.
71. Moriello KA, Newbury S, Steinberg H. Five observations of a third morphologically distinct feline *Demodex* mite. *Vet Dermatol* 2013; 24: 460–462.
72. Saari SA, Juuti KH, Palojarvi JH et al. *Demodex gatoi*-associated contagious pruritic dermatosis in cats—a report from six households in Finland. *Acta Vet Scand* 2009; 51: 40.
73. Morris DO, Beale KO. Feline demodicosis. In: Bonagura JD, ed. *Kirk's current veterinary therapy XIII*. Philadelphia, PA: W.B. Saunders; 2000:580–582.
74. Milley C, Dryden M, Rosenkrantz W et al. Comparison of parasitic mite retrieval methods in a population of community cats. *J Feline Med Surg* 2017; 19: 657–664.
75. Silbermayr K, Joachim A, Litschauer B et al. The first case of *Demodex gatoi* in Austria, detected with fecal flotation. *Parasitol Res* 2013; 112: 2,805–2,810.
76. Fondati A. Efficacy of daily oral ivermectin in the treatment of 10 cases of generalized demodicosis. *Vet Dermatol* 1996; 7: 99–104.
77. Mueller RS, Meyer D, Bensignor E et al. Treatment of canine generalized demodicosis with a 'spot-on' formulation

- containing 10% moxidectin and 2.5% imidacloprid (Advocate, Bayer Healthcare). *Vet Dermatol* 2009; 20: 441–446.
78. Mueller RS, Bettenay SV. Scraping, fine-needle aspiration and biopsy of skin and subcutaneous tissues. In: Ettinger SJ, Feldman EC, Cote E, eds. *Textbook of veterinary internal medicine*, 8th edition. St Louis, MO: Elsevier; 2017:342–345.
 79. Beco L, Fontaine F, Bergvall K et al. Comparison of skin scrapes and hair plucks for detecting *Demodex* mites in canine demodicosis, a multicentre, prospective study. Annual Conference of the European Society of Veterinary Dermatology/European College of Veterinary Dermatology 2007; 18: 381 (Abstract).
 80. Bensignor E. Comparaison de trois techniques diagnostiques de demodécie a *Demodex canis* chez le chien [Comparison of three diagnostic techniques of *Demodex canis* demodicosis in the dog]. *Prat Med Chir Anim Comp* 2003; 38: 167–171.
 81. Fondati A, De Lucia M, Furiani N et al. Prevalence of *Demodex canis*-positive healthy dogs at trichoscopic examination. *Vet Dermatol* 2010; 21: 146–151.
 82. Pereira AV, Pereira SA, Gremiao ID et al. Comparison of acetate tape impression with squeezing versus skin scraping for the diagnosis of canine demodicosis. *Aust Vet J* 2012; 90: 448–450.
 83. Vogelnest L, Garibotto V. Evaluation of the squeeze tape impression for the diagnosis of canine demodicosis. *Vet Dermatol* 2016; 27 (Suppl 1): 38 (Abstract).
 84. Lousada R, Fonseca I, Nunes T et al. New atraumatic technique for *Demodex canis* diagnosis. *Vet Dermatol* 2016; 27(Suppl 1): 114 (Abstract).
 85. Saridomichelakis MN, Koutinas AF, Farmaki R et al. Relative sensitivity of hair pluckings and exudate microscopy for the diagnosis of canine demodicosis. *Vet Dermatol* 2007; 18: 138–141.
 86. Moskvina TV, Shchelkanov MY, Begun MA. Fecal flotation in the detection of canine *Demodex* mites. *Vet Dermatol* 2018; 29: 263–264 (Letter).
 87. American Academy of Veterinary Dermatology. Dermatologists recommend neutering of canine patients with demodicosis. *J Am Vet Med Assoc* 1983; 182(1): 1,048.
 88. Bruzinska-Schmidhalter R, Nett-Mettler CS. Spontaneous remission in canine generalized demodicosis - predisposing factors. *Vet Dermatol* 2011; 22: 301 (Abstract).
 89. Scott DW. Untreated generalized demodicosis in young dogs. *Vet Dermatol* 2012; 23: 174–175 (Letter).
 90. Bergvall K, Ahman S, Varjonen K et al. Genetic and clinical evaluation of canine juvenile demodicosis. *Vet Dermatol* 2016; 27 (Suppl 1): 114 (Abstract).
 91. Kuznetsova E, Bettenay S, Nikolaeva L et al. Influence of systemic antibiotics on the treatment of dogs with generalized demodicosis. *Vet Parasitol* 2012; 188: 148–155.
 92. Folz SD, Geng S, Nowakowski LH et al. Evaluation of a new treatment for canine scabies and demodicosis. *J Vet Pharm Ther* 1978; 1: 199–204.
 93. Franc M, Soubeyrou H. Le traitement de la démodécie du chien par un collier a 9% d'amitraz [Treatment of canine demodicosis with a collar containing 9% amitraz]. *Rev Méd Vét* 1986; 137: 583–586.
 94. Hnilica K, Little SE, Medleau LM. Evaluation of the use of Preventic (9% amitraz) collars as an adjunct treatment for generalized canine demodicosis. *Vet Dermatol* 2003; 14: 224 (Abstract).
 95. Fourie LJ, Kok DJ, du Plessis A et al. Efficacy of a novel formulation of metaflumizone plus amitraz for the treatment of demodectic mange in dogs. *Vet Parasitol* 2007; 150: 268–274.
 96. Rosenkrantz W. Efficacy of metaflumizone plus amitraz for the treatment of juvenile and adult onset demodicosis in dogs: pilot study of 24 dogs. *Vet Dermatol* 2009; 20: 227 (Abstract).
 97. Tarallo VD, Lia RP, Sasanelli M et al. Efficacy of Amitraz plus Metaflumizone for the treatment of canine demodicosis associated with *Malassezia pachydermatis*. *Parasit Vectors* 2009; 2: 13.
 98. Fourie J, Dumont P, Halos L et al. Efficacy of a topical application of Certifect(R) (fipronil 6.26% w/v, amitraz 7.48% w/v, (S)-methoprene 5.63% w/v) for the treatment of canine generalized demodicosis. *Parasite* 2013; 20: 46.
 99. Oberkirchner U, Linder K, Dunston S et al. Metaflumzone-amitraz (Promeris) -associated pustular acantholytic dermatitis in 22 dogs: evidence suggests contact drug-triggered pemphigus foliaceus. *Vet Dermatol* 2011; 22: 435–448.
 100. Folz SD, Kakuk TJ, Henke CL et al. Clinical evaluation of amitraz as a treatment for canine demodicosis. *Vet Parasitol* 1984; 16: 335–341.
 101. Muller GH. Amitraz treatment of demodicosis. *J Am Anim Hosp Assoc* 1983; 19: 435–441.
 102. Bussieras J, Chermette R. Amitraz and canine demodicosis. *J Am Anim Hosp Assoc* 1986; 22: 779–782.
 103. Hamann F, Wedell H, Bauer J. Zur Demodikose des Hundes [Demodicosis of the dog]. *Kleintierpraxis* 1997; 42: 745–754.
 104. Hugnet C, Bruchon-Hugnet C, Royer H et al. Efficacy of 1.25% amitraz solution in the treatment of generalized demodicosis (eight cases) and sarcoptic mange (five cases) in dogs. *Vet Dermatol* 2001; 12: 89–92.
 105. Kwochka KW, Kunkle GA, Foil CS. The efficacy of amitraz for generalized demodicosis in dogs: A study of two concentrations and frequencies of application. *Comp Cont Educ* 1985; 7: 8–17.
 106. Lemarie S, Hosgood G, Foil CS. A retrospective study of juvenile- and adult-onset generalized demodicosis in dogs (1986–1991). *Vet Dermatol* 1996; 7: 3–10.
 107. Medleau L, Willemsse T. Efficacy of daily amitraz therapy for refractory, generalized demodicosis in dogs: two independent studies. *J Am Anim Hosp Assoc* 1995; 31: 246–249.
 108. Paradis M. New approaches to the treatment of canine demodicosis. *Vet Clin North Am Small Anim Pract* 1999; 29: 1,425–1,436.
 109. Scott DW, Walton DK. Experiences with the use of amitraz and ivermectin for the treatment of generalized demodicosis in dogs. *J Am Anim Hosp Assoc* 1985; 21: 535–541.
 110. Shirk ME. The efficacy of amitraz in treatment for demodectic mange: a field study. *Vet Med Sm Anim Clin* 1983; 78: 1,059–1,062.
 111. Kamboj DS, Singh KB, Avtar S et al. Studies on the therapeutic efficacy of amitraz, deltamethrin and ivermectin on canine demodicosis. *Indian Vet J* 1993; 70: 61–64.
 112. Farmer H, Seawright AA. The use of amitraz (N1-(2,4-dimethylphenyl)-N-[(2,4-dimethylphenyl)imino]-methyl]-N-methylmethanimid amide) in demodecticosis in dogs. *Aust Vet J* 1980; 56: 537–541.
 113. Kwochka K. Demodicosis. In: Griffin C, Macdonald J, Kwochka KW, eds. *Current veterinary dermatology*. St Louis, MO: Mosby Year Book, 1993: 72–84.
 114. Dhoria S, Agarwal R. Amitraz, an underrecognized poison: A systematic review. *Indian J Med Res* 2016; 144: 348–358.
 115. Craig M. Demodicosis. In: Foster AP, Foil CS, eds. *BSAVA Manual of Small Animal Dermatology*, 2nd edition. Gloucester, UK: British Small Animal Veterinary Association, 2003; 153–158.
 116. Campbell WC, Fisher MH, Stapley EO et al. Ivermectin: a potent new antiparasitic agent. *Science* 1983; 221: 823–828.
 117. Plumb DP. *D. P. Plumb's Veterinary Drug Handbook*. 8th edition. Stockholm, WI: Wiley Blackwell, 2015; 796–802.
 118. Paradis M, Page N. Topical (pour-on) ivermectin in the treatment of chronic generalized demodicosis in dogs. *Vet Dermatol* 1998; 9: 55–59.
 119. Medleau L, Ristic Z, McElveen DR. Daily ivermectin for the treatment of generalized demodicosis in dogs. *Vet Dermatol* 1996; 7: 209–212.
 120. Mueller RS, Hastie K, Bettenay SV. Daily oral ivermectin for the treatment of generalised demodicosis in 23 dogs. *Aust Vet Pract* 1999; 29: 132–136.

121. Delayte EH, Otsuka M, Larsson CE et al. Efficacy of systemic macrocyclic lactones (ivermectin and moxidectin) for the treatment of generalized canine demodicosis. *Arq Bras Med Vet Zootec* 2006; 58: 31–38.
122. Ristic Z, Medleau L, Paradis M et al. Ivermectin for treatment of generalized demodicosis in dogs. *J Am Vet Med Assoc* 1995; 207: 1,308–1,310.
123. Paterson T, Halliwell R, Fields P et al. Canine generalized demodicosis treated with varying doses of a 2.5% moxidectin + 10% imidacloprid spot-on and oral ivermectin: Parasitocidal effects and long-term treatment outcomes. *Vet Parasitol* 2014; 205: 687–696.
124. Mueller RS, Bettenay SV. A proposed new therapeutic protocol for the treatment of canine mange with ivermectin. *J Am Anim Hosp Assoc* 1999; 35: 77–80.
125. Merola VM, Eubig PA. Toxicology of avermectins and milbemycins (macrocyclic lactones) and the role of P-Glycoprotein in dogs and cats. *Vet Clin North Am Small Anim Pract* 2012; 42: 313–333.
126. Clarke DL, Lee JA, Murphy LA et al. Use of intravenous lipid emulsion to treat ivermectin toxicosis in a Border Collie. *J Am Vet Med Assoc* 2011; 239: 1,328–1,333.
127. Trailovic SM, Nedeljko J. Central and peripheral neurotoxic effects of ivermectin in rats. *J Vet Med Sci* 2011; 73: 591–599.
128. Barbet JL, Snook T, Gay JM et al. ABCB1-1 Delta (MDR1-1 Delta) genotype is associated with adverse reactions in dogs treated with milbemycin oxime for generalized demodicosis. *Vet Dermatol* 2009; 20: 111–114.
129. Mealey KL, Bentjen SA, Gay JM et al. Ivermectin sensitivity in collies is associated with a deletion mutation of the *mdr1* gene. *Pharmacogenetics* 2001; 11: 727–733.
130. Mealey KL, Meurs KM. Breed distribution of the ABCB1-1Δ (multidrug sensitivity) polymorphism among dogs undergoing ABCB1 genotyping. *J Am Vet Med Assoc* 2008; 233: 921–924.
131. Bissonnette S, Paradis M, Daneau I et al. The ABCB1-1Δ mutation is not responsible for subchronic neurotoxicity seen in dogs of non-collie breeds following macrocyclic lactone treatment for generalized demodicosis. *Vet Dermatol* 2009; 20: 60–66.
132. Dunn ST, Hedges L, Sampson KE et al. Pharmacokinetic interaction of the antiparasitic agents ivermectin and spinosad in dogs. *Drug Metab Dispos* 2011; 39: 789–795.
133. Schrickx JA. Spinosad is a potent inhibitor of canine P-glycoprotein. *Vet J* 2014; 200: 195–196.
134. Miller WH Jr, Scott DW, Wellington JR et al. Clinical efficacy of milbemycin oxime in the treatment of generalized demodicosis in adult dogs. *J Am Vet Med Assoc* 1993; 203: 1,426–1,429.
135. Mueller RS, Bettenay SV. Milbemycin oxime in the treatment of canine demodicosis. *Aust Vet Practit* 1995; 25: 122–126.
136. Holm BR. Efficacy of milbemycin oxime in the treatment of canine generalized demodicosis: a retrospective study of 99 dogs (1995–2000). *Vet Dermatol* 2003; 14: 189–195.
137. Sasaki Y, Kitagawa H, Murase S. Susceptibility of rough-coated collies to milbemycin oxime. *Jap J Vet Sci* 1990; 52: 1,269–1,271.
138. Besignor E, Carlotti D. Moxidectin in the treatment of generalized demodicosis in dogs. A pilot study: 8 cases. In: Kwochka KW, Willemse T, Von Tscharner C, eds. *Advances in Veterinary Dermatology*, volume 3. Oxford: Butterworth-Heinemann, 1998; 554–555 (Abstract).
139. Burrows A. Evaluation of the clinical efficacy of two different doses of moxidectin in the treatment of generalized demodicosis in the dog. In: Proceedings of the Annual Meeting of the Australian College of Veterinary Scientists. Gold Coast, Australia: 1997.
140. Wagner R, Wendlberger U. Field efficacy of moxidectin in dogs and rabbits naturally infested with *Sarcoptes* spp., *Demodex* spp. and *Psoroptes* spp. mites. *Vet Parasitol* 2000; 93: 149–158.
141. Paul AJ, Hutchens DE, Firkins LD et al. Dermal safety study with imidacloprid/moxidectin topical solution in the ivermectin-sensitive Collie. *Vet Parasitol* 2004; 121: 285–291.
142. Paterson TE, Halliwell RE, Fields PJ et al. Treatment of canine-generalized demodicosis: a blind, randomized clinical trial comparing the efficacy of Advocate(Bayer Animal Health) with ivermectin. *Vet Dermatol* 2009; 20: 447–455.
143. Colombo S, Leone F, Vercelli A et al. Monthly application of 10 per cent moxidectin and 2.5 per cent imidacloprid spot-on to prevent relapses in generalised demodicosis: a pilot study. *Vet Rec* 2012; 171: 272.
144. Johnstone IP. Doramectin as a treatment for canine and feline demodicosis. *Aust Vet Practit* 2002; 32: 98–103.
145. Murayama N, Shibata K, Nagata M. Efficacy of weekly oral doramectin treatment in canine demodicosis. *Vet Rec* 2010; 167: 63–64.
146. Hutt JC, Prior C, Shipstone M. Treatment of canine generalised demodicosis using weekly injections of doramectin: 232 cases in the USA (2002–2012). *Vet Dermatol* 2015; 26: 345–350.
147. Cordero AM, Quek S, Mueller RS. Doramectin in the treatment of generalized demodicosis. *Vet Dermatol* 2018; 29: 104–e41.
148. Cordero AM, Sheinberg-Waisburd G, Romero NC. Early onset canine generalized demodicosis. *Vet Dermatol* 2018; 29: 173 (letter).
149. Weber T, Selzer PM. Isoxazolines: a novel chemotype highly effective on ectoparasites. *Chem Med Chem* 2016; 11: 270–276.
150. Lahm GP, Cordova D, Barry JD et al. 4-Azolyphenyl isoxazoline insecticides acting at the GABA gated chloride channel. *Bioorg Med Chem Lett* 2013; 23: 3,001–3,006.
151. Gassel M, Wolf C, Noack S et al. The novel isoxazoline ectoparasiticide fluralaner: selective inhibition of arthropod gamma-aminobutyric acid- and L-glutamate-gated chloride channels and insecticidal/acaricidal activity. *Insect Biochem Mol Biol* 2014; 45: 111–124.
152. Shoop WL, Hartline EJ, Gould BR et al. Discovery and mode of action of afoxolaner, a new isoxazoline parasiticide for dogs. *Vet Parasitol* 2014; 201: 179–189.
153. Kilp S, Ramirez D, Allan MJ et al. Pharmacokinetics of fluralaner in dogs following a single oral or intravenous administration. *Parasit Vectors* 2014; 7: 85.
154. Walther FM, Allan MJ, Roepke RK et al. The effect of food on the pharmacokinetics of oral fluralaner in dogs. *Parasit Vectors* 2014; 7: 84.
155. Walther FM, Allan MJ, Roepke RK et al. Safety of fluralaner chewable tablets (Bravecto), a novel systemic antiparasitic drug, in dogs after oral administration. *Parasit Vectors* 2014; 7: 87.
156. Kilp S, Ramirez D, Allan MJ et al. Comparative pharmacokinetics of fluralaner in dogs and cats following single topical or intravenous administration. *Parasit Vectors* 2016; 9: 296.
157. Fourie JJ, Liebenberg JE, Horak IG et al. Efficacy of orally administered fluralaner (Bravecto) or topically applied imidacloprid/moxidectin (Advocate(R)) against generalized demodicosis in dogs. *Parasit Vectors* 2015; 8: 187.
158. Karas-Tecza J, Dawidowicz J. Efficacy of fluralaner for the treatment of canine demodicosis. *Vet Dermatol* 2015; 26: 307 (Abstract).
159. Duangkaew L, Larsuprom L, Anukkul P et al. A field trial in Thailand of the efficacy of oral fluralaner for the treatment of dogs with generalized demodicosis. *Vet Dermatol* 2018; 29: 208–e74.
160. Rohdich N, Roepke RK, Zschiesche E. A randomized, blinded, controlled and multi-centered field study comparing the efficacy and safety of Bravecto (fluralaner) against Frontline (fipronil) in flea- and tick-infested dogs. *Parasit Vectors* 2014; 7: 83.
161. Food and Drug Administration. *New Animal Drug Application 141-426, 2014. Bravecto Fluralaner*. Available at: <https://animaldrugsatfda.fda.gov/adafda/app/search/public/document/downloadFoi/1502>. Accessed 9 November 2019.

162. Kunkle B, Daly S, Dumont P et al. Assessment of the efficacy of orally administered afoxolaner against *Rhipicephalus sanguineus sensu lato*. *Vet Parasitol* 2014; 201: 226–228.
163. Kunkle BN, Drag MD, Chester TS et al. Assessment of the onset of action of afoxolaner against existing adult flea (*Ctenocephalides felis*) infestations on dogs. *Vet Parasitol* 2014; 201: 204–206.
164. Drag M, Saik J, Harriman J et al. Safety evaluation of orally administered afoxolaner in 8-week-old dogs. *Vet Parasitol* 2014; 201: 198–203.
165. Dryden MW, Smith V, Chwala M et al. Evaluation of afoxolaner chewables to control flea populations in naturally infested dogs in private residences in Tampa FL, USA. *Parasit Vectors* 2015; 8: 286.
166. Letendre L, Huang R, Kvaternick V et al. The intravenous and oral pharmacokinetics of afoxolaner used as a monthly chewable antiparasitic for dogs. *Vet Parasitol* 2014; 201: 190–197.
167. Food and Drug Administration. *New Animal Drug Application 141–406, 2013. Nexgard Afoxolaner*. Available at: <https://anim.fda.gov/adafda/app/search/public/document/downloadFoi/911>. Accessed 9 September 2019.
168. Drag M, Saik J, Harriman J et al. Safety evaluation of orally administered afoxolaner and milbemycin oxime in eight-week-old dogs. *J Vet Pharmacol Ther* 2017; 40: 447–453.
169. Chavez F. Case report of afoxolaner treatment for canine demodicosis in four dogs naturally infected with *Demodex canis*. *Int J Appl Res Vet Med* 2016; 14: 123–127.
170. Mueller RS, Shipstone MA. Update on the diagnosis and treatment of canine demodicosis (workshop report). In: Torres SMF, Roudebush P, eds. *Advances in Veterinary Dermatology*, volume 8. Wiley Online Books, 2017: 206–207. Available at: <https://onlinelibrary.wiley.com/doi/book/10.1002/9781119278368>. Accessed 9 November 2019.
171. Murayama N, Oshima Y. Efficacy of oral afoxolaner for the treatment of canine generalized demodicosis in Japan. *Vet Dermatol* 2018; 29: 269–270 (Abstract).
172. Beugnet F, Halos L, Larsen D et al. Efficacy of oral afoxolaner for the treatment of canine generalised demodicosis. *Parasite* 2016; 23: 14.
173. Lebon W, Beccati M, Bourdeau P et al. Efficacy of two formulations of afoxolaner (NexGard® and NexGard Spectra®) for the treatment of generalised demodicosis in dogs, in veterinary dermatology referral centers in Europe. *Parasit Vect* 2018; 11: 506.
174. Breitschwerdt E, Little S, Rugg D. Sarolaner—a novel isoxazoline—addresses the need for enhanced flea and tick control. *Vet Parasitol* 2016; 222: 1–2 (Editorial).
175. McTier TL, Chubb N, Curtis MP et al. Discovery of sarolaner: A novel, orally administered, broad-spectrum, isoxazoline ectoparasiticide for dogs. *Vet Parasitol* 2016; 222: 3–11.
176. Cherni JA, Mahabir SP, Six RH. Efficacy and safety of sarolaner (Simparica) against fleas on dogs presented as veterinary patients in the United States. *Vet Parasitol* 2016; 222: 43–48.
177. Six RH, Becskei C, Mazaleski MM et al. Efficacy of sarolaner, a novel oral isoxazoline, against two common mite infestations in dogs: *Demodex* spp. and *Otodectes cynotis*. *Vet Parasitol* 2016; 222: 62–66.
178. Becskei C, Cuppens O, Mahabir SP. Efficacy and safety of sarolaner against generalized demodicosis in dogs in European countries: a non-inferiority study. *Vet Dermatol* 2018; 29: 203–e72.
179. Snyder DE, Wiseman S, Liebenberg JE. Efficacy of lotilaner (Credelio), a novel oral isoxazoline against naturally occurring mange mite infestations in dogs caused by *Demodex* spp. *Parasit Vectors* 2017; 10: 532.
180. Scott DW, Schultz RD, Baker EB. Further studies on the therapeutic and immunologic aspects of generalized demodectic mange in the dog. *J Am Anim Hosp Assoc* 1976; 12: 203–213.
181. Kraiss A, Gothe R. Demodikosetherapie mit Muramyl dipeptide und Amitraz [Demodex therapy with muramyl peptide and amitraz]. *Kleintierpraxis* 1983; 28: 9–30.
182. Mojzisova J, Paulik S, Bajova V et al. The immunomodulatory effect of levamisole with the use of amitraz in dogs with uncomplicated generalized demodicosis. *Vet Medical-Czech* 1987; 42: 307–311.
183. Pekmezci D, Pekmezci GZ, Guzel M et al. Efficacy of amitraz plus inactivated parvovirus ovis in the treatment of canine generalised demodicosis. *Vet Rec* 2014; 174: 556.
184. Figueiredo C, Viana JA, Curi PR. Clinical evaluation of the effect of vitamin E in the treatment of generalized canine demodicosis. In: Ihrke PJ, Mason IS, White SD, eds. *Advances in Veterinary Dermatology*, volume 2. Oxford: Pergamon Press; 1993: 247–261.
185. Gilbert PA, Griffin CE, Rosenkrantz WS. Serum vitamin E levels in dogs with pyoderma and generalized demodicosis. *J Am Anim Hosp Assoc* 1992; 28: 407–410.
186. Stromberg BE, Nutting WB. Adaptive features of the exoskeleton and 'pigment' deposits in *Demodex* spp. (Demodicidae). *Acarologia* 1972; 14: 605–611.
187. Schwassmann M, Kunkle GA, Hepler DI et al. Use of lufenuron for treatment of generalized demodicosis in dogs. *Vet Dermatol* 1997; 8: 11–18.
188. Das SS. Efficacy of 'Maggacite', an indigenous preparation against demodecticosis in dogs and its comparison with deltamethrin. *Indian Vet J* 1998; 75: 157–158.
189. Nayak DC, Tripathy SB, Dey PC et al. Therapeutic efficacy of some homeopathic preparations against experimentally produced demodicosis in canines. *Indian Vet J* 1998; 75: 342–344.
190. Das SS. Efficacy of Pestoban aerosol spray in treatment of canine demodecticosis. *J Vet Parasitol* 1993; 7: 67–69.
191. Losson B, Benakhla A. Efficacité du closantel dans le traitement de la gale demodectique du chien [Effectiveness of closantel in the treatment of canine demodectic mange]. *Ann Méd Vét* 1980; 124: 521–526.
192. Gabbert N, Feldman BF. Feline demodex. *Fel Practice* 1976; 6: 32–33.
193. Stogdale L, Moore DJ. Feline demodicosis. *J Am Anim Hosp Assoc* 1982; 18: 427–432.
194. Conroy JD, Healey MC, Bane AG. New *Demodex* sp. infesting a cat: a case report. *J Am Anim Hosp Assoc* 1982; 18: 405–407.
195. McDougal BJ, Novak CP. Feline demodicosis caused by an unnamed *Demodex* mite. *Comp Cont Educ Sm Anim* 1986; 8: 820–822.
196. Chesney CJ. An unusual species of demodex mite in a cat. *Vet Rec* 1988; 123: 671–673.
197. Medleau LM, Brown CA, Brown SA et al. Demodicosis in cats. *J Am Anim Hosp Assoc* 1988; 24: 85–90.
198. Morris DO. Contagious demodicosis in three cats residing in a common household. *J Am Anim Hosp Assoc* 1996; 32: 350–352.
199. Carlotti DN, Lemaire C, Lavayssiere J et al. La demodectie feline. A propos de trois cas [Feline demodicosis. Three cases]. *Prat Med Chir Anim Comp* 1986; 21: 203–208.
200. Guaguère E. Demodectie feline: etude retrospective de 9 cas [Feline demodex: a retrospective study of nine cases]. *Prat Med Chir Anim Comp* 1993; 28: 31–36.
201. Cowan LA, Campbell K. Generalized demodicosis in a cat responsive to amitraz. *J Am Vet Med Assoc* 1988; 192: 1,442–1,444.
202. Short J, Gram D. Successful treatment of *Demodex gato* with 10% imidacloprid/1% moxidectin. *J Am Anim Hosp Assoc* 2016; 52: 68–72.
203. Matricoti I, Maina E. The use of oral fluralaner for the treatment of feline generalised demodicosis: a case report. *J Small Anim Pract* 2017; 58: 476–479.
204. Jimenez-Acosta F, Planas L, Penneys N. *Demodex* mites contain immunoreactive lipase. *Arch Dermatol* 1989; 125: 1,436–1,437 (Letter).
205. Namazi MR. A possible role for human follicle mites in skin's defense against bacteria. *Indian J Dermatol Venereol Leprol* 2007; 73: 270 (Letter).

206. Ravera I, Altet L, Francino O *et al.* Development of a real-time PCR to detect *Demodex canis* DNA in different tissue samples. *Parasitol Res* 2011; 108: 305–308.
207. Zewe CM, Altet L, Lam ATH *et al.* Afoxolaner and fluralaner treatment do not impact on cutaneous *Demodex* populations of healthy dogs. *Vet Dermatol* 2017; 28: 468–e107.
208. Zhao C, Casida JE. Insect gamma-aminobutyric acid receptors and isoxazoline insecticides: toxicological profiles relative to the binding sites of [(3)H]fluralaner, [(3)H]-4'-ethynyl-4-n-propyl-bicycloorthobenzoate, and [(3)H]ivermectin. *J Agric Food Chem* 2014; 62: 1,019–1,024.

Résumé

Contexte – La démodécie est une maladie fréquente en médecine vétérinaire des petits animaux, dans le monde entier, avec plusieurs options diagnostiques et thérapeutiques.

Objectifs – Fournir un consensus des recommandations sur le diagnostic, la prévention et le traitement de la démodécie du chien et du chat.

Matériels et méthodes – Les auteurs ont formé un groupe d'experts (GP) et ont revu la littérature disponible antérieure à décembre 2018. Le GP a préparé une revue détaillée de la littérature et a fourni des recommandations sur des sujets choisis. Un premier document a été présenté au forum de dermatologie animale d'Amérique du nord à Maui, HI, USA (Mai 2018) et au congrès européen de dermatologie vétérinaire à Dubrovnik (Septembre 2018) et était disponible sur le WorldWideWeb aux membres des organisations de l'association mondiale de dermatologie vétérinaire pendant trois mois. Les commentaires ont été sollicités et les réponses, incorporées au document final.

Conclusions – Chez les jeunes chiens atteints de démodécie généralisée, les facteurs génétiques et immunologiques semblent jouer un rôle dans la pathogénie et les chiens atteints ne devraient pas se reproduire. Chez les chiens et les chats âgés, les pathologies immunosuppressives sous-jacentes contribuant à la démodécie doivent être explorées. Des raclages profonds sont la méthode de diagnostic de choix pour la démodécie, mais les trichogrammes et les tests à la cellophane adhésive peuvent aussi être utiles dans certaines conditions. L'amitraz, les lactones macrocycliques et plus récemment les isoxazolines ont montré leur bonne efficacité dans le traitement de la démodécie canine. Le choix du traitement doit être fait sur la base de la législation locale, de la disponibilité des molécules et des paramètres individuels. Les preuves pour l'efficacité d'un traitement de la démodécie féline sont fortes pour le lime sulfur et les bains d'amitraz.

RESUMEN

Introducción – la demodicosis es una enfermedad común en la práctica veterinaria de animales pequeños en todo el mundo con una variedad de opciones de diagnóstico y terapéuticas.

Objetivos – Proporcionar recomendaciones consensuadas sobre el diagnóstico, prevención y tratamiento de la demodicosis en perros y gatos.

Métodos y materiales – los autores sirvieron como Panel de Recomendaciones (GP) y revisaron la literatura disponible antes de diciembre de 2018. El GP preparó una revisión detallada de la literatura y formuló pautas sobre temas seleccionados. Se presentó un borrador del documento en el Foro de Dermatología Veterinaria de América del Norte en Maui, HI, EE. UU. (Mayo de 2018) y en el Congreso Europeo de Dermatología Veterinaria en Dubrovnik, Croacia (septiembre de 2018) y se puso a disposición a través de WorldWideWeb para las organizaciones miembros de la Asociación Mundial de Dermatología Veterinaria por un período de tres meses. Se solicitaron comentarios y las respuestas se incorporaron al documento final.

Conclusiones – en perros jóvenes con demodicosis generalizada, los factores genéticos e inmunológicos parecen desempeñar un papel en la patogénesis y los perros afectados no deben ser criados. En perros y gatos viejos, se deben explorar condiciones inmunosupresoras subyacentes que contribuyen a la demodicosis. Los raspados profundos de la piel son el estándar principal de diagnóstico para la demodicosis, pero los tricogramas y las preparaciones de compresión con cinta adhesiva también pueden ser útiles en ciertas circunstancias. El amitraz, las lactonas macrocíclicas y más recientemente las isoxazolinas han demostrado una buena eficacia en el tratamiento de la demodicosis canina. La selección terapéutica debe guiarse por la legislación farmacéutica local, la disponibilidad de medicamentos y los parámetros de casos individuales. La evidencia del tratamiento exitoso frente a la demodicosis felina es más clara para los baños de inmersión en azufre de cal y baños de amitraz.

Zusammenfassung

Hintergrund – Die Demodikose ist weltweit eine häufige Erkrankung in der Kleintierpraxis mit unterschiedlichen diagnostischen und therapeutischen Optionen.

Ziele – Die Erstellung von Consensus Empfehlungen in Bezug auf Diagnose, Vorbeugung und Behandlung der Demodikose bei Hunden und Katzen.

Methoden und Materialien – Die AutorInnen wirkten als Guideline Panel (GP) und führten eine Review der Literatur durch, die vor Dezember 2018 zur Verfügung stand. Die GP erstellten eine detaillierte Literaturretrospektive und machten Empfehlungen über ausgewählte Themen. Ein Auszug des Dokuments wurde beim North American Veterinary Dermatology Forum in Maui, HI, USA (Mai 2018) sowie beim European

Veterinary Dermatology Congress in Dubrovnik, Kroatien (September 2018) präsentiert und wurde über das WorldWideWeb den Mitgliedern der Organisationen der World Association for Veterinary Dermatology für eine Dauer von drei Monaten zur Verfügung gestellt. Es wurde um Kommentare gebeten und die Antworten in das Abschlussdokument inkludiert.

Schlussfolgerungen – Bei jungen Hunden mit einer generalisierten Demodikose scheinen genetische und immunologische Faktoren bei der Pathogenese eine Rolle zu spielen und man sollte mit betroffenen Rassen nicht züchten. Bei alten Hunden und Katzen sollten die zugrundeliegenden immunsupprimierenden Ursachen, die zur Demodikose beitragen, untersucht werden. Tiefe Hautgeschabsel sind der diagnostische Goldene Standard zur Diagnose einer Demodikose, aber Trichogramme und Klebestreifen Quetschpräparate können unter gewissen Umständen auch nützlich sein. Amitraz, Macrozyklische Laktone und unlängst häufiger Verwendung findende Isoxazoline haben eine gute Wirksamkeit bei der Behandlung der Demodikose des Hundes gezeigt. Die therapeutische Selektion sollte sich nach der lokalen Legislation der Medikamente richten, der Verfügbarkeit der Medikamente sowie individueller Fallparameter. Die Evidenz für eine erfolgreiche Behandlung der Demodikose der Katze ist am stärksten für Kalksulphat und Amitraz Bäder.

要約

背景 – ニキビダニ症は世界中の小動物獣医診療において一般的な疾患であり、さまざまな診断および治療オプションがある。

目的 – 本研究の目的は、犬および猫のニキビダニ症の診断、予防および治療に関するコンセンサスの推奨事項を提供することである。

材料と方法 – 著者らはガイドラインパネル (GP) を務め、2018年12月までに入手可能な文献をレビューした。GPは詳細な文献レビューを作成し、選択したトピックに関する推奨事項を作成した。本文書の草案は、米国ハワイ州マウイで開催された北米獣医フォーラム (2018年5月) およびクロアチアのドブロブニクで開催された欧州獣医学会 (2018年9月) で発表され、WorldWideWebを介して3か月間、世界獣医皮膚科学会の会員組織に公開された。コメントを求め、回答を最終文書に組み込んだ。

結論 – 若齢発症性汎発性ニキビダニ症では、遺伝的および免疫学的因子が病因に関与しているようであり、罹患犬を繁殖に用いるべきではない。老犬および猫では、ニキビダニ症の原因となる基礎的な免疫抑制状態を調査する必要がある。深部皮膚スクレーピングは、ニキビダニ症診断のゴールドスタンダードであるが、特定の状況では抜毛検査やテープスクイズ作成も役立つ場合がある。アミトラズ、大環状ラクトン、さらに最近ではイソキサゾリン系化合物のすべてが、犬ニキビダニ症の治療において良好な有効性を実証している。治療法の選択は、その地域の薬事法、薬の入手可能性、および個々の症例パラメータに基づいて行う必要がある。猫ニキビダニ症の治療成功に対するエビデンスは、石灰硫黄の浸漬とアミトラズ浴で最も強い。

摘要

背景 – 在世界各地的小动物兽医临床中，蠕形螨病都是一种常见疾病，其诊断和治疗的选择有多种。

目的 – 提供诊断、预防和治疗犬猫蠕形螨病的共识性建议。

方法和材料 – 作者们成立指导小组(GP)，回顾了2018年12月之前现存的文献。指导小组编写了详细的文献综述，并就选定的主题提出了建议。在美国夏威夷毛伊岛举办的北美兽医皮肤医学论坛(2018年5月)，以及克罗地亚杜布罗夫尼克举办的欧洲兽医皮肤病大会(2018年9月)，都公布了文件草案，并通过世界兽医皮肤病协会会员组织的世界范围网站发布三个月。征求了意见，并将答复纳入文件的最终版本。

结论 – 在全身性蠕形螨的幼犬身上，遗传和免疫因素似乎在发病机制中起作用，发病犬不应繁殖。在老年犬猫中，应寻找导致蠕形螨病的潜在免疫抑制疾病。皮肤深刮是诊断蠕形螨病的金标准，但在某些情况下，毛发形态和挤压胶带状制片也可能有用。双甲脞、大环内酯类和新近上市的异恶唑啉类药物，均显示出良好的治疗犬蠕形螨病的疗效。治疗选择应以当地药物法规、药物可获得性和个案参数为指导。成功治疗猫蠕形螨病最给力的是硫磺剂和双甲脞。

Resumo

Contexto – A demodicose é uma doença comum na prática veterinária de pequenos animais em todo o mundo, com uma variedade de opções diagnósticas e terapêuticas disponíveis.

Objetivos – Fornecer um consenso de recomendações sobre o diagnóstico, prevenção e tratamento da demodicose em cães e gatos.

Métodos e materiais – Os autores constituíram um Painel de Diretrizes (GP) e revisaram toda a literatura disponível até dezembro de 2018. O GP preparou uma revisão detalhada da literatura e fez recomendações sobre os tópicos selecionados. Um rascunho do documento foi apresentado no Fórum de Dermatologia Veterinária da América do Norte em Maui, HI, EUA (maio de 2018) e no Congresso Europeu de Dermatologia Veterinária em Dubrovnik, Croácia (setembro de 2018) e foi disponibilizado via WorldWideWeb às organizações membros da Associação Mundial de Dermatologia Veterinária por um período de três meses. Foram solicitados comentários e as respostas foram incorporadas ao documento final.

Conclusões – Em cães jovens com demodicose generalizada, fatores genéticos e imunológicos parecem desempenhar um papel na patogênese e os cães afetados não devem ser utilizados na reprodução. Em cães e gatos idosos, deve-se investigar condições imunossupressoras subjacentes que contribuem para a

demodicose. O raspado cutâneo profundo é o padrão-ouro para diagnóstico de demodicose, mas o trico-grama e o exame parasitológico por fita adesiva também podem ser úteis em determinadas circunstâncias. O amitraz, as lactonas macrocíclicas e mais recentemente as isoxazolinias demonstraram boa eficácia no tratamento da demodicose canina. A seleção terapêutica deve ser orientada pela legislação local de medicamentos, disponibilidade de fármacos e parâmetros individuais de cada caso. O tratamento da demodicose felina possui evidências de sucesso mais fortes com banhos de calda sulfocálcica e banhos de amitraz.